A CLINICAL STUDY ON NEUROTIZED FREE FLAPS FOR RECONSTRUCTION OF HEAD AND NECK DEFECTS

Dissertation submitted in partial fulfilment of the requirements for the degree of

M.Ch. (Plastic surgery) – Branch III

THE TAMILNADU DR.M.G.R. MEDICAL UNIVERSITY

CHENNAI

AUGUST 2013

Certificate

This is to certify that **DR.S.SUJA,** *post graduate (2010 – 2013) in the Department of Plastic, Reconstructive & Faciomaxillary Surgery, Madras Medical College & Rajiv Gandhi Government General Hospital, Chennai-03, has done dissertation titled,* **"*A CLINICAL STUDY ON NEUROTIZED FREE FLAPS FOR RECONSTRUCTION OF HEAD AND NECK DEFECTS*",** *under my direct guidance and supervision in partial fulfilment of the regulations laid down by* **THE TAMILNADU DR.M.G.R. MEDICAL UNIVERSITY, GUINDY, CHENNAI-32** *for the degree of* **MASTER OF CHIRURGERY**, *plastic & reconstructive surgery (branch III) degree examination.*

GUIDE

PROF. R. GOPINATH M.Ch,

PROFESSOR AND HEAD OF DEPARTMENT

DEPARTMENT OF PLASTIC, RECONSTRUCTIVE & FACIOMAXILLARY SURGERY

MADRAS MEDICAL COLLEGE & RGGGH

CHENNAI 600 003.

Declaration

I solemnly declare that this dissertation ***"A CLINICAL STUDY ON NEUROTIZED FREE FLAPS FOR RECONSTRUCTION OF HEAD AND NECK DEFECTS"*** was prepared by me in the Department of Plastic, Reconstructive and Faciomaxillary Surgery, Madras Medical College & Rajiv Gandhi Government General Hospital, Chennai between 2010 and 2013.

This dissertation is submitted to **THE TAMILNADU DR. M.G.R. MEDICAL UNIVERSITY, CHENNAI-32** in partial fulfilment of the university requirements for the award of degree of **MCh PLASTIC SURGERY**.

Place: Chennai **signature of the candidate**

Date:

Acknowledgement

I gratefully acknowledge and sincerely thank the Dean, Madras Medical College, Chennai, for granting me permission to utilize the facilities of the institution for my study.

I am extremely grateful to my teacher and guide Prof. R. Gopinath M.Ch., Professor and Head of the department of Plastic, Reconstructive and Faciomaxillary Surgery, Madras Medical College, Chennai, who helped me in all stages of my study. I am thankful to him for his timely suggestions, unending patience, constant encouragement and scholarly guidance.

I am extremely grateful to Prof. Udesh Ganapathy M.Ch., for his guidance and support.

I am extremely grateful to Prof. K. Gopalakrishnan M.Ch., for his constant support and encouragement

I am extremely grateful to my retired Prof. K. V. Alala Sundaram M.Ch, Prof. J. Palani velu M.Ch and Prof. Anand Subramaniam M.Ch (Late)

I express my thanks to Dr. Saravanan, Dr. S. Sridevi, Dr. C. Selvakumar, Dr. T.M.Balakrishnan, Dr. K. Bhoopathy, and Dr. Ramadevi for their sustained encouragement in my work and study.

Last, but not the least, I thank all my patients, without their help and co-operation this study would not have been possible

CONTENTS

Page No

1. **INTRODUCTION**
2. **OBJECTIVES**
3. **REVIEW OF LITERATURE**
    - **LITERATURE**
    - **FUNCTIONAL ANATOMY**
    - **RECONSTRUCTIVE OPTIONS**
4. **MATERIALS AND METHODS**
5. **DATAS**
6. **RESULTS**
7. **ANALYSIS AND DISCUSSION**
8. **SUMMARY AND CONCLUSION**
9. **ANNEXURES**
    a) **BIBLIOGRAPHY**
    b) **PROFORMA**
    c) **MASTER CHART**

INTRODUCTION

Reconstruction of head and neck defects is a difficult challenge for the reconstructive surgeon because of its complex anatomy and function. The objective of head and neck reconstruction include the restoration of anatomy, function and appearance

Ideally reconstruction should provide tissue that resembles in geometry and form.

Head and neck defects can be from trauma or post tumour excision.They can be resurfaced in many ways. Local flaps, regional flaps, and free flaps can be used in resurfacing. Because of the complexity of the defects, and the damage of the tissue following radiotherapy, micro vascular surgery is often the only option in head and neck reconstruction in case of malignancy

In this clinical study, neurotisation of free flaps is done in view of early functional recovery, (ie) nerve of the flap is coapted with the nerve at the recipient defect. Micro vascular surgery is done under operating microscope .

Functional recovery of upper aero digestive tract is assessed speech, swallowing, mastication.

Dexterity in swallowing, mastication, and speech function necessitates good sensory feedback. When insensate free flaps were used for lining in the cheek, tongue, and soft palate areas, absence of sensory feed back or absence of proprioception from insensate areas prevent the coordinated, dexterous functions of upper aero digestive tract. Speech, mastication and swallowing necessitate close coordination between sensory and motor pathway of the nervous system. A neurotised flap goes long way in bringing the proprioception and necessary sensory feedback into the post oncological resection areas. Thereby early recovery of upper aero digestive tract functions are expected to happen.

This is our hypothesis which has been confirmed by the clinical study.

OBJECTIVE

1. To assess the early functional recovery of the upper aero digestive tract in head and neck reconstruction with immediate neurotised free flaps.
2. To assess the sensory recovery as well in the reconstructed flap as the surrounding structure.
3. To compare the functional outcome with non neurotised free flaps used for head and neck reconstruction

REVIEW OF LITERATURE

LITERATURE OF HEAD AND NECK RECONSTRUCTION:

Edgerton in 1951 introduced the concept of primary reconstruction following tumor resection in the head and neck. In 1963 McGregor advanced the concept of primary reconstruction after tumor resection with the use of a laterally based forehead flap. In 1965 Bakamjian introduced the deltopectoral flap, which became the reconstructive workhorse for over a decade.

In the 1970s the concept of the musculocutaneous flap was introduced. The pectoralis major musculocutaneous flap described by Ariyan in 1979 was of paramount importance because it enabled the single-stage transfer of large amounts of well vascularized skin for ablative defects of the upper aerodigestive tract, face, and skull base. At the same time, other musculocutaneous flaps were being used as a frontline reconstructive technique in head and neck defects. Quillen and Barton popularized the use of the pedicled latissimus dorsi musculocutaneous flap. McCraw and Dibbell and Ariyan popularized the superior trapezius musculocutaneous flap, which was an extension of Conley's work.

The advent of microvascular free tissue transfer revolutionized reconstructive surgery in the head and neck. Microvascular surgery has the advantage of providing more flap options to reliably and precisely replace tissue defects in one stage. Free flaps are well vascularized and offer greater flexibility in spatial positioning while reducing unnecessary bulk and eliminating the tethering effect of avascular pedicle. while at one time the cure was often considered worse than the disease, now the majority of patients can be restored to a good functional and cosmetic state through primary reconstruction.

Reports exist in the literature of spontaneous intraoral reinnervation of regional flaps. Heimanson reported return of deep pressure sensation in noninnervated free flaps to lower extremities but could not demonstrate neural ingrowth from surrounding tissues. It was theorized that heavy touch stimuli were activating pressure sensors in tissues under the flaps or nerve fibers that had grown into the deep layers of the flap. No flap had light touch or pain sensation. Urken and colleagues in 1990 published a report on the use of an innervated radial forearm flap for oral reconstruction. The medial and lateral cutaneous nerves of the forearm were coapted to the stumps of the greater auricular nerve. The patients were able to differentiate between hot and cold sensations on the flap. The sensory feedback was not appropriate for the defect, however, as the patient perceived oropharyngeal stimuli on the flap as stimulation of the ear.

Hayden reports the results of coapting the lateral cutaneous nerve of transferred radial forearm flaps to stumps of the glossopharyngeal and lingual nerves within oral and pharyngeal resections. Not only did return of sensation differentiate between hot and cold, but the patients could demonstrate two-point discrimination. Most importantly, carefully choosing the right recipient nerve will allow return of sensation appropriate to the defect.

Urken offers an overview of the concepts involved in restoration or preservation of sensation in the oral cavity. The author notes the selection of an appropriate sensory recipient nerve should be based on two important criteria. First, it should have normal cortical representation for the region undergoing reconstruction (lingual nerve to tongue, inferior alveolar nerve to lips, etc). oral cavity — lingual nerve and inferior alveolar nerve. If unavailable, consider greater auricular or cervical plexus. Second, the recipient nerve should not be sacrificed unless deemed necessary for oncologic purposes during tumor ablation.

Boyd and colleagues review the results of partial glossectomy and floor of mouth reconstruction with sensory radial forearm flaps in 8 patients. The lateral antebrachial cutaneous nerve was coapted to the lingual nerve

FUNCTIONAL ANATOMY OF THE ORAL CAVITY:

The oral cavity extends from vermilion to the junction of the hard and soft palate superiorly. It extends up to the circumvallate papillae of the tongue inferiorly. The oral cavity includes the lips, buccal mucosa, upper and lower alveolar ridges, hard palate, retromolar trigone, floor of the mouth, and anterior two thirds of the tongue.

Each above mentioned structure participates in speech, mastication, bolus preparation, bolus manipulation and deglutition.

The oral sphincter participates in mastication, speech, and deglutition. It prevents escape of saliva and provides water tight closure in preparation of bolus.

Alveolar ridges are elevated above the floor of mouth and are lined by nonmobile mucosa. They direct the salivary flow and collect the food during bolus preparation. The floor of mouth is important for the mobility of the tongue.

The anterior tongue has both sensory and motor functions including proprioception, pain, taste, speech and bolus manipulation. The mobility of tongue is needed for speech. The hard palate plays the counterpart role against the tongue for speech, bolus preparation and its transit.

The buccal mucosa lines the cheek and it is important for mastication and deglutition. So during reconstruction the flap the flap should be mobile to allow for mastication and should be thin to avoid entrapment by the teeth.

The final push of the food bolus is by the posterior tongue. The tonsillar pillars separate the oropharynx and nasopharynx and prevent the nasal regurgitation during speech and swallowing.

RECONSTRUCTIVE OPTIONS

ORAL CAVITY RECONSTRUCTION:

Even though the oral cavity is composed of distinct anatomic elements participating in various functions including mastication, speech, and deglutition, single function accomplishment often requires the simultaneous participation of each anatomic element.

It is important to consider the general health of the patient, as well as the overall defect, for reconstructive options. Carcinoma of oral cavity tends to occur in patients with other co-morbidity.

AVAILABLE OPTIONS:

1. Primary closure
2. It is done in case of small defects especially of floor of the mouth and tongue
3. Local flaps

   They provide the best colour and texture match and may bring sensate flap. But it is of limited value in large defects and irradiated skin.
4. Skin grafts:

   If only the lining or cover is deficient, we can use skin grafts. But in case of irradiation, it can not be used.

5. Pedicled myo cutaneous flap is an option for larger defects. But it tends to distort the intraoral reconstruction or leave unsightly external bridge.
6. Free flaps are best option because of single stage reconstruction and complex defect reconstruction with combination of different composite tissues such as bone, mucosa, and muscle.

   Due to the complexity of the defects and the damage of the tissue following radiotherapy, micro vascular surgery is often the only option for oral cavity reconstruction.
7. One step ahead is our clinical study of neurotised free flap.

MANDIBLE RECONSTRUCTION:

The mandible contributes to airway maintenance. It is also important in speech, deglutition, and mastication. Also it determines the asthesis of the lower face.

Specific function goals include temporo mandibular joint action preservation and dental rehabilitation. There may be a need for reconstruction of segments of mandible either lateral [L], central [C], or hemi mandible [H] or combination of more than one segment.

AVAILABLE OPTIONS:

1. Non vascularised bone graft

2. Prosthetic mandible reconstruction

Problem of extrusion is there.

3. Metal reconstruction plate

Risk of infection and exposure, risk of plate ftracture, preclusion of dental reconstruction are there. It requires water tight closure

4. Pedicled osteo cutaneous flaps (eg) trapezius osteo cutaneous flap with spine of scapula, pectoralis osteo cutaneous flap with rib. Draw backs are wastage of flap volume in pedicle region, and availability of bone is limited.

5. Most reliable soft tissue coverage is provided by micro vascular free flap which has abundant tissue and inset without tension. Currently, fibula is the choice. Other donor sites are radius, the scapula and ilium.

6. Neurotised free flaps

MAXILLARY RECONSTRUCTION:

According to the qualitative and quantitative defects, maxillary defects are classified as

1. Limited –type I
2. Subtotal – type II
3. Total – type III
4. Orbito maxillary – type IV

AVAILABLE OPTIONS:

1. Bone graft
2. Radial forearm fasciocutaneous flap
3. Radial forearm osteocutaneous flap
4. Rectus abdominis myocutaneous free flap
5. Temporalis muscle pedicle flap.

In our clinical study, we have done only neurotised radial forearm flap and free fibular flap, for immediate reconstruction of head and neck defects either post excisional or post traumatic.

The post operative functional outcome of immediate neurotisation is assessed by both sensory and motor recovery. The sensory recovery is assessed by two point discrimination, touch, pain and crude touch, and temperature. The motor recovery is assessed by means of functions of upper aero digestive tract such as speech, swallowing and mastication.

OPERATIVE STEPS

FREE FIBULAR FLAP

Reconstruction of the mandible, especially when the defect involves the anterior mandible, is a formidable challenge to the reconstructive surgeon. Vascularized bone has been well accepted for use in reconstruction of the mandible. Of all the flaps currently available, the fibula has become the flap of choice at many centers.

If no skin paddle is required, the fibula is harvested from the ipsilateral leg. If skin tissue is needed in the reconstruction, the contralateral leg is selected, allowing for placement of the skin paddle intraorally

ANATOMY

The fibula bone lies in the deep posterior compartment, just lateral to the tibia. The upper end of the fibula does not comprise any part of the knee joint but articulates with the undersurface of the tibial plateau. The lower end of the fibula is the lateral malleous and is involved in ankle-joint articulation. There are four muscles surrounding the fibula: the extensor digitorum longus superiorly, the posterior tibialis medially, the peroneal muscles laterally, and the flexor hallucis longus inferiorly. The blood supply to the fibula comes from the peroneal vessels, which are one of three terminal branches of the popliteal artery. The peroneal vessels lie between the tibialis posterior muscle and the flexor hallucis longus. The posterolateral intermuscular septum is the terminal end of the transverse crural septum; it is through this septum that the cutaneous perforators run. It is therefore important to harvest as much of this septum as possible when harvesting the skin paddle.

FLAP DESIGN AND DIMENSIONS

The fibular head at the knee, the peroneal nerve just below the fibular head, and the lateral malleolus at the ankle are marked. Hash marks are drawn at 10, 15, 20, and 25 cm from the fibular head. The skin paddle is centered between the hash marks, taking into account the mandibular area being resected: this determines whether the proximal or distal part of the fibula is used.

OPERATIVE TECHNIQUE

The designated leg is elevated and a tourniquet inflated. Because the peroneal artery and vein course along the medial side of the fibula, a lateral approach is used in beginning the dissection. An anterior incision down through the deep muscle fascia is made; inclusion of this fascia is crucial. As the dissection continues posteriorly to the posterolateral intermuscular septum, the peroneal muscles are exposed. The anterior surface of the septum then is followed down the fibula, and the peroneal muscles are elevated from the lateral and anterior surfaces of the bone. The anterolateral intermuscular septum is divided close to the fibula to prevent injury to the anterior tibial neurovascular bundle, and the dissection continues down through the interosseous membrane. Next a posterior incision is made down through the deep muscle fascia, and the skin paddle is elevated to the edge of the soleus muscle.  

An incision about 1 cm deep is made in the soleus muscle 1 cm from its lateral border. The bone is now cut to the required length with an oscillating saw. The bone should not be cut within 8 cm of the lateral malleolus because the tibiofibular ligaments may be injured, causing ankle-joint instability. The proximal cut in the fibula should be made as high as possible without damaging the peroneal nerve. Even if the proximal fibula will not be used, it should be harvested to expose the trifurcation of the leg vessels, facilitating the pedicle dissection. 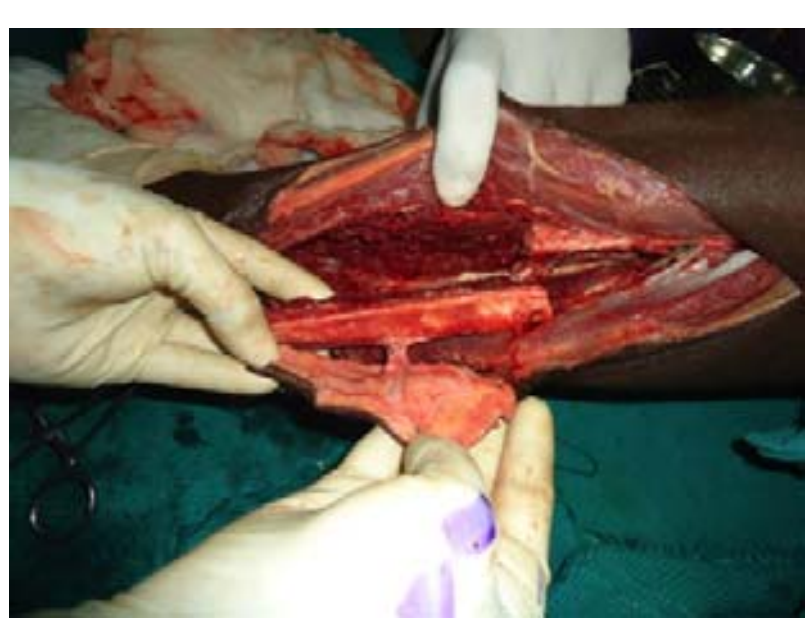

Once the fibula is cut, it is retracted laterally, and the dissection proceeds from distal to proximal and from medial to lateral. Medially, the peroneal vessels are located, followed down to their distal aspect, ligated, and divided.

After elevating the flap, the tourniquet is released and any residual bleeding controlled. By this time, the ablative team should have the mandible exposed and ready for resection. Before osteotomies are undertaken, the reconstruction team bends a reconstruction plate over the native mandible, stabilizes the plate with screws posterior to the planned mandibulectomy cuts, and then removes the plate and screws. Thus, the original shape of the mandible will be reestablished and the condyles correctly positioned relative to the neomandible.  The ablative team now completes the resection while the reconstruction team uses the shaped reconstruction plate (as a template) to cut the fibula with closing wedge osteotomies; during this sequence, the fibula is perfused in situ. Bone fragments are fixed before transfer to limit ischemia time. As soon as the resection is finished and tumor-free margins have been confirmed by frozen sections, the neuro vascular pedicle is divided and the flap is transferred to the recipient site.

First, the skin paddle is inset along the tongue because this is technically easier to do before the bone is in place. Next the bony ends of the fibula/reconstruction-plate complex are trimmed (while being moderately compressed) to make a good fit, and then the plate is fastened to the native mandible with the screws and holes used previously.

The external carotid artery and internal jugular vein used in an end-to-side configuration are the recipient vessels of choice. **After micro vascular anastomosis, the superficial peroneal nerve is coapted with the recipient nerve in the resected area according to the site.** After the anastomoses are completed, the flap is checked for adequate revascularization, flap insetting is completed, and the wound is closed over suction drains. The leg incision is also closed over suction drains, and a bulky dressing and posterior leg splint are applied.

Postoperatively, the patient is managed and monitored in the surgical intensive care unit. If the patient is stable after 24 to 48 hours and transferred to a regular nursing floor, activity is slowly increased, as tolerated. A feeding tube is used in all patients who have a mandibular, floor of the mouth, or oropharyngeal reconstruction. During the first postoperative week, most patients are seen for physical therapy to initiate walking and range-of-motion exercises, particularly in the donor area. Following a fibular harvest, the posterior leg splint is removed on the third or fourth day, and the patient begins cautious ambulation in physical therapy. If there is a skin graft to the donor site, walking is postponed for 7 days, and the leg is wrapped with an elastic bandage when it is dependent. In uncomplicated cases without a skin graft, the patient is discharged 10 to 14 days after surgery.

RADIAL FOREARM FREE FLAP

The radial forearm flap is a fasciocutaneous flap based on the radial artery and venae comitantes, together with the subcutaneous forearm veins. Several reports already have demonstrated the versatility, usefulness, and reliability of this flap both as a pedicled flap in reconstructive surgery of the hand and as a free flap in the expanding field of free tissue transfer. This flap can be used as either a fasciocutaneous flap or as an osteofasciocutaneous flap for reconstructing defects resulting from excision of intraoral malignancies.

ANATOMY

Much of the skin of the forearm is supplied by the radial artery, which is covered proximally by the fleshy belly of the brachioradialis. It soon emerges distally between the brachioradialis and the flexor carpi radialis to lie superficially, covered only by skin, subcutaneous tissue, and the deep fascia.

The artery, together with its two venae comitantes, is invested in a condensation of the deep fascia known as the lateral intermuscular septum. This septum separates the flexor and extensor compartments of the forearm and is attached to the periosteum of the radius distal to the insertion of pronator teres.

The artery gives off branches that pass through the deep fascia to supply the underlying flexor muscles and branches that spread out on the deep fascia to form a fascial plexus and supply the overlying skin. By means of this vascular network, the radial artery can supply the skin of the palmar and radial aspects of the forearm and provide a periosteal blood supply to the distal radius.

Venous drainage of the forearm flap is provided by two venae comitantes that accompany the artery and a variable pattern of subcutaneous forearm veins that drain into the cephalic, basilic, and median cubital veins. Routinely, both venous systems communicate by means of a constant branch from the venae comitantes, which drains into the median cubital vein.

The forearm flap is ideally suited for free-tissue transfer because the artery can be readily palpate for much of its length and the superficial subcutaneous veins of the forearm are easily identified. The diameter of the artery, usually in excess of 3 mm, remains relatively constant from its origin to the wrist joint, making anastomosis of either proximal or distal ends equally straightforward.

Furthermore, the absence of significant arterial disease, particularly atheroma in elderly patients, has been most remarkable.

FLAP DESIGN AND DIMENSIONS

Using a template, a radial forearm flap can be designed to replace the amount of resected tissue accurately, thereby minimizing distortion and functional disturbance within the oral cavity. The radial artery, which is subcutaneous for much of its length in the forearm, can be palpated and its course marked on the skin surface. The superficial subcutaneous forearm veins are similarly marked, and the appropriately designed flap is outlined.

The arteriovenous system on which the forearm flap is based is capable of supplying all the skin of the forearm from above the elbow to the wrist, except for a narrow strip overlying the ulna posteriorly. In practice, such large flaps are not required in intraoral reconstruction.

The quality of the skin and the length of the vascular pedicle required for easy anastomosis most often influence the choice of donor site. The presence and distribution of hair on the forearm may influence site selection, although such hairs tend to be short and fine and cause little trouble following flap transfer. Distally designed flaps are thinner than proximal flaps, and this is most evident in woman and obese patients. In addition, the distal design is chosen when bone is to be included (as an osteocutaneous flap) or when a long vessel pedicle is required. The advantages of the distal flap have to be balanced against the donor defect. In practice, the mid-forearm flap has proved to be most useful. It combines the advantages of ease of elevation and donor defect found in proximal flaps with the skin quality of distal flaps.

An added bonus of the midforearm flap lies in the possibility of raising both a proximal and distal vascular pedicle, allowing a certain freedom with regard to subsequent anastomosis because either end of the artery can be anastomosed in an antegrade or retrograde fashion and the free end ligated. Alternatively, the artery can be used as an interpositional graft. In this situation, the arterial flow appears to be more physiologic, matching more closely the preexisting conditions in the forearm.

OPERATIVE TECHNIQUE

Elevation of the forearm flap is straightforward and can be performed simultaneously with the intraoral resection without altering the patient's position on the operating table. It has seemed prudent to anastomose both a superficial vein and a deep vena comitantes. In other cases, useful information can be gained by selective clamping of the veins prior to transferring the flap. Where doubt exists, it is safe to perform the arterial anastomosis first, and following release of the arterial clamps, the pattern of venous outflow can be accurately determined and the appropriate vein then chosen for anastomosis. The length of venous pedicle should never be a problem, since this can be extended well above the elbow, and in this situation, a single venous anastomosis obviously will provide drainage for both superficial and accompanying venous systems.

A tourniquet is placed around the upper arm. The arm is *incompletely* exsanguinated using an Esmarch or an Ace bandage before dissection commences. The skin flap is incised around its periphery, and dissection is carried down to the underlying muscle fascia. Dissection is carried through the subcutaneous tissue, and the selected venous system is traced proximally. If an innervated flap is desired, all the subcutaneous nerves entering the flap should be preserved in a sheath of fascia; they tend to lie just superficial to the deep fascia. Precise identification of the nerves is best made in the proximal forearm, where they are large and located next to the cephalic and basilic veins. These nerves and their relevant branches then can be traced distally into the proximal margin of the flap.

The ulnar side of the flap then is elevated at a level just superior to the deep fascia, working toward the intermuscular septum between the brachioradialis and the flexor carpi radialis. Approximately 1 cm on the ulnar side of this septum, the deep fascia is incised, and dissection then passes under it. Preservation of the deep fascia in this way facilitates skin grafting of the donor site. Dissection proceeds over the surface of the flexor carpi radialis tendon, leaving paratenon behind. It then extends around the radial edge of the tendon into the space beneath. Usually, the superficial fibers of the flexor digitorum superficialis muscle are now visible. Dissection around the radial side of this muscle allows it to be retracted in an ulnar direction. When this is done, the fibers of the flexor pollicis longus are seen arising from the flat anterior surface of the distal radius and the adjacent interosseous membrane. This completes dissection on the ulnar side.

The radial dissection is similar to that on the ulnar side. It passes immediately superficial to the deep fascia until a point is reached 1 cm lateral to the intermuscular septum, where the deep fascia is divided and dissection then proceeds at this deeper level. The brachioradialis tendon is seen, and the dissection hugs this tendon in the same way as the ulnar dissection hugged that of the flexor carpi radialis. Paratenon is preserved. Once around the ulnar border of the brachioradialis tendon, the plane of dissection remains close to its undersurface. A space filled with loose adventitial tissue is soon entered. Blunt dissection in this space exposes the dorsoradial *bare area* of the radius. Distally, the radial artery and its venae comitantes are easily identified; these are ligated and divided. The brachioradialis tendon is elevated somewhat from its attachment to the distal radius; however, care is taken to preserve its distal attachment. This maneuver allows a little more radius to be included in the osteocutaneous flap because the attachment of the brachioradialis defines the distal limit of the bone graft. The cephalic vein is ligated and divided distally, as are other small veins in the region.

It should be noted that the superficial branch of the radial nerve passes through the deep portion of the flap and is visible during the radial dissection. This nerve is *not* to be used for innervations purposes. The nerve can be easily dissected from the undersurface of the flap, and *it is virtually* *never necessary to sacrifice it.*

The secondary defect can be grafted.

MATERIALS AND METHODS

The materials for the clinical study are taken from the clinical records of the patients presented to plastic and reconstructive surgery department with post excisional or post traumatic complex soft tissue defects of the head and neck region in Rajiv Gandhi Government General Hospital, Chennai, during the period October 2010 to October 2012.

In our clinical series, we have studied the functional outcome of the immediate neurotisation of the free flaps in head and neck reconstruction in 42 patients in whom reconstruction done with neurotised radial forearm flap and free fibular flap.

Careful planning and a multi disciplinary team approach are essential. We need to explain in details to the patient about the ablative procedure and reconstructive options in head and neck reconstruction

Pre-operative assessment includes evaluation of the patient's general health with particular attention to the cardio pulmonary, renal and nutritional status. Many patients are tobacco chewers and smokers. As there is increase in risk of thrombosis in micro vascular surgery, abstinence from smoking should be there at least for 2-4weeks before and after surgery.

The head and neck reconstruction is planned by assessing the qualitative and quantitative tissue loss after resection or trauma. Appropriate free flap with its donor nerve for immediate neurotisation is decided.

Routine pre-operative laboratory tests should include complete blood count, blood chemistry panel, clotting studies, blood grouping and typing, chest radiograph, and electrocardiogram. If needed pulmonary function tests, cardiac assessment and nutritional assessment which includes serum protein and albumin are done.

Defects are ideally repaired at the time of resection. The advantages of immediate reconstruction with neurotised free flap are numerous. The defects are widely exposed, recipient neuro vascular dissection needs little additional dissection. Single stage treatment maximises the time of 'normal' living without need of readmissions and procedures.

By immediate neurotisation of free flaps, there is early recovery of 2 point discrimination and thereby early recovery of function of upper aero digestive tract. Finally, the patient's attitude is greatly improved when form and function are promptly restored.

INCLUSION CRITERIA

All the head and neck defects where there is good prospectus for immediate neurotisation of the free flaps are included.

EXCLUSION CRITERIA

- Those cases of failed free flaps
- Those cases where neurotisation are not done, are excluded from this study

Carcinoma palate – maxillary reconstruction with neurotised free fibula


POST MAXILLECTOMY DEFECT


INCISION FOR FREE FIBULA


FIBULA SEGMENT WITH SKIN PADDLE


OSTEEOTOMY DONE FOR SHAPING

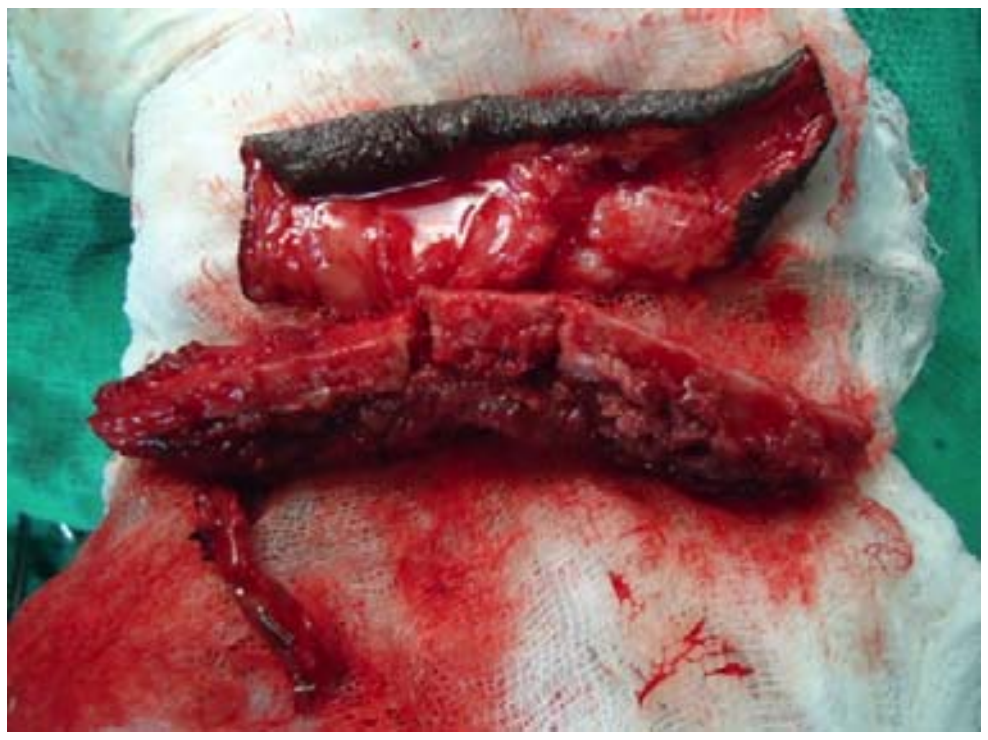
HARVESTED FREE FIBULA ALONG WITH NEUROVASCULAR BUNDLE


FLAP INSET BEING GIVEN


MICRO VASCULAR ANASTOMOSIS AND NEURAL ANASTOMOSIS DONE


INSET

POST TRAUMATIC OSTEOMYELITIC MAXILLARY DEFECT RECONSTRUCTED WITH NEUROTISED FREE FIBULAR FLAP

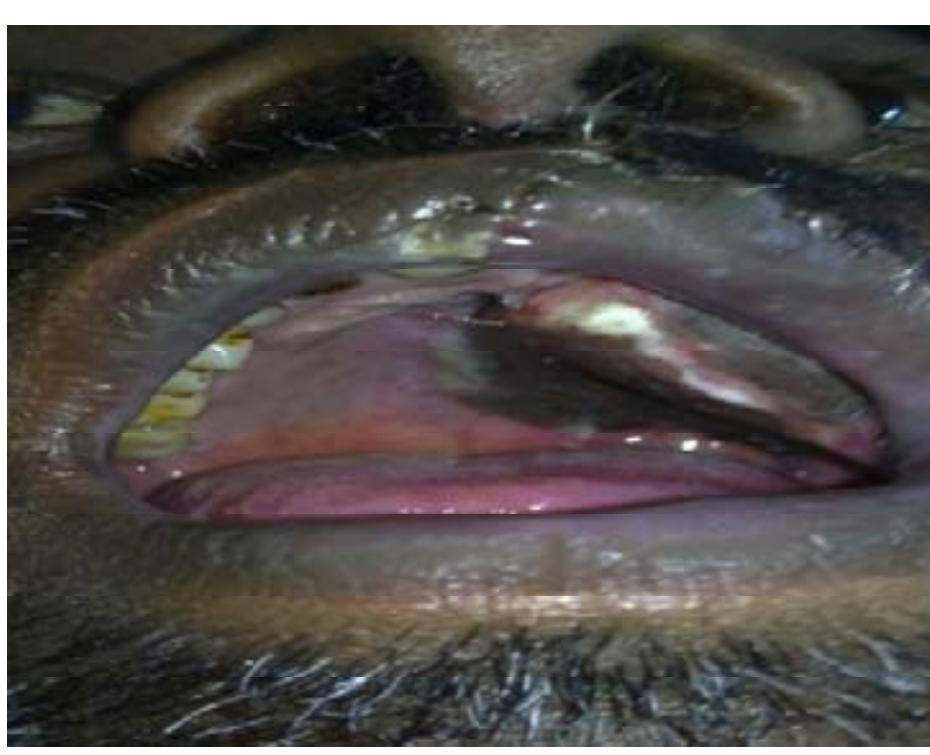

CARCINOMA SOFT PALATE –RECONSTRUCTION BY NEUROTISED RADIAL FOREARM FLAP WITH PALMARIS LONGUS SLING FOR ELEVATION OF RECONSTRUCTED PALATE






CARCINOMA OF TONGUE – RECONSTRUCTION BY NEUROTISED RADIAL FLAP




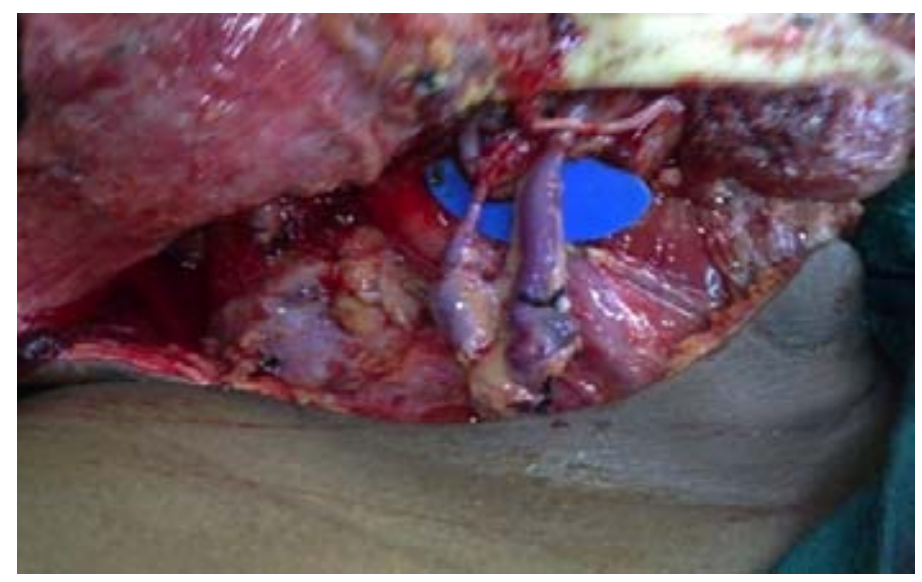

AMINOBLASTOMA MANDIBLE- RECONSTRUCTION DONE WITH NEUROTISED FREE FIBULA

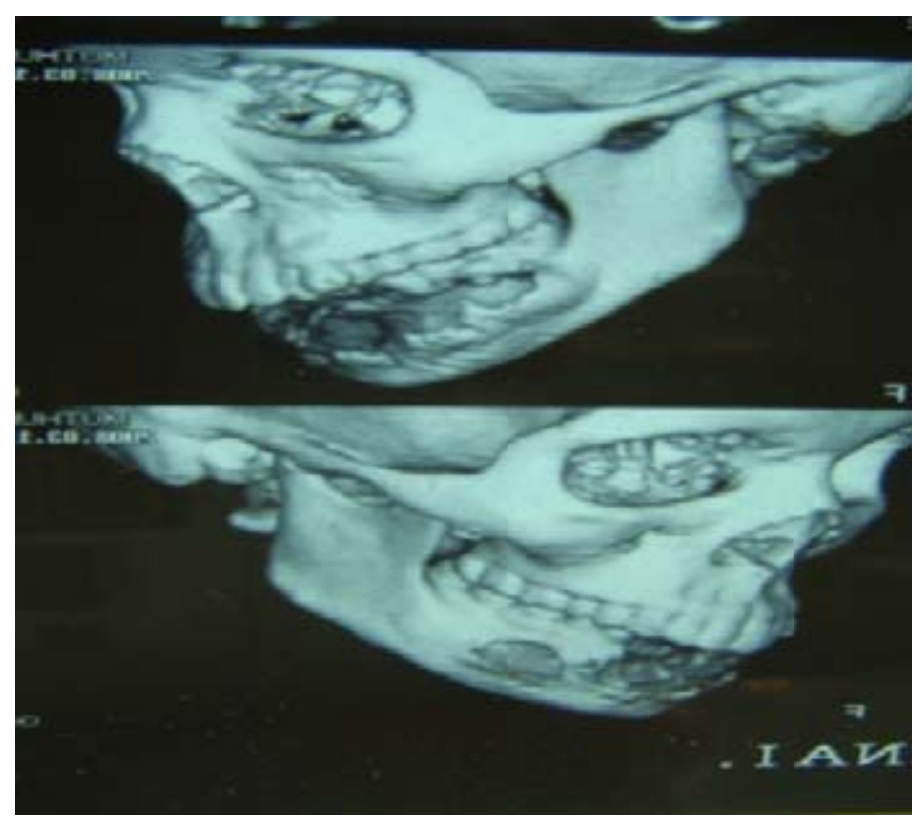

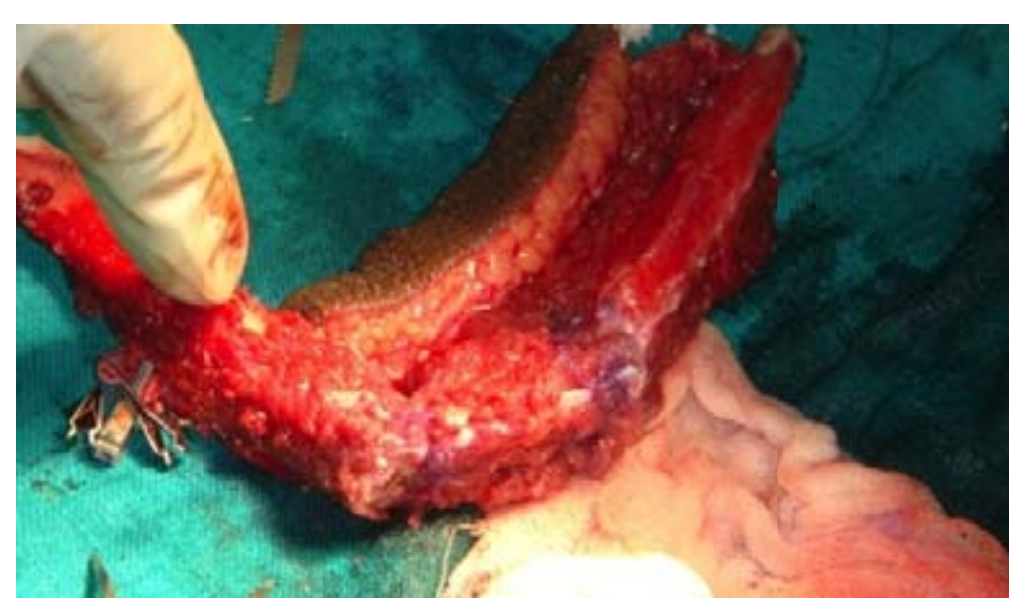

PATINT WAITING FOR OSSEO INTEGRATED DENTAL IMPLANTS

CARCINOMA CHEEK – RECONSTRUCTION WITH NEUROTISED RADIAL FOREARM FLAP







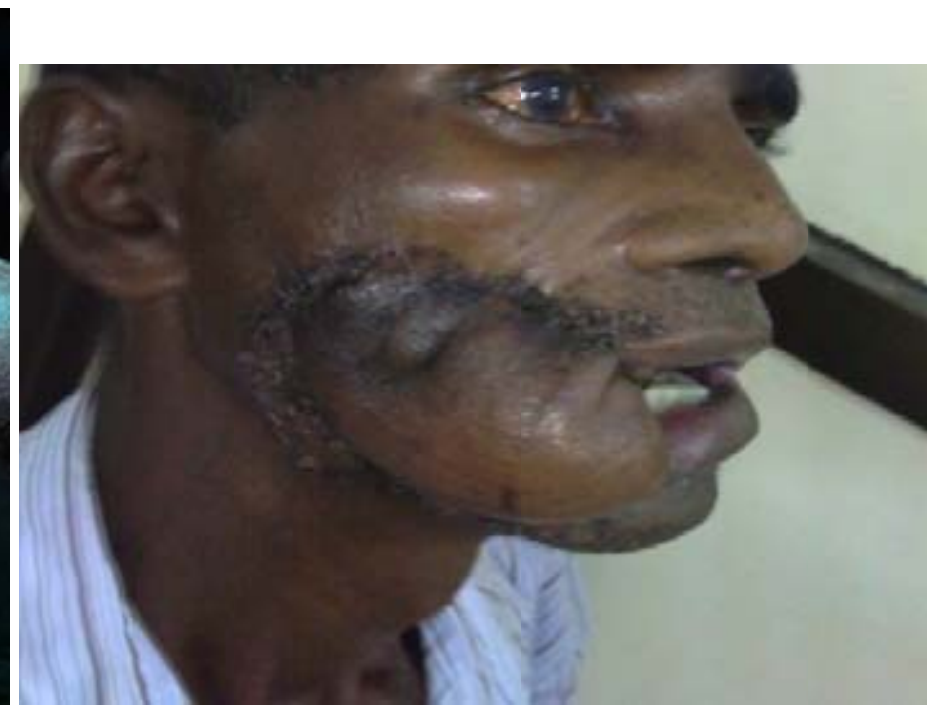

CARCINOMA CHEEK ABUTING INTO MANDIBULAR ALVEOLUS-RECONSTRUCTION DONE WITH NEUROTISED FREE FIBULA

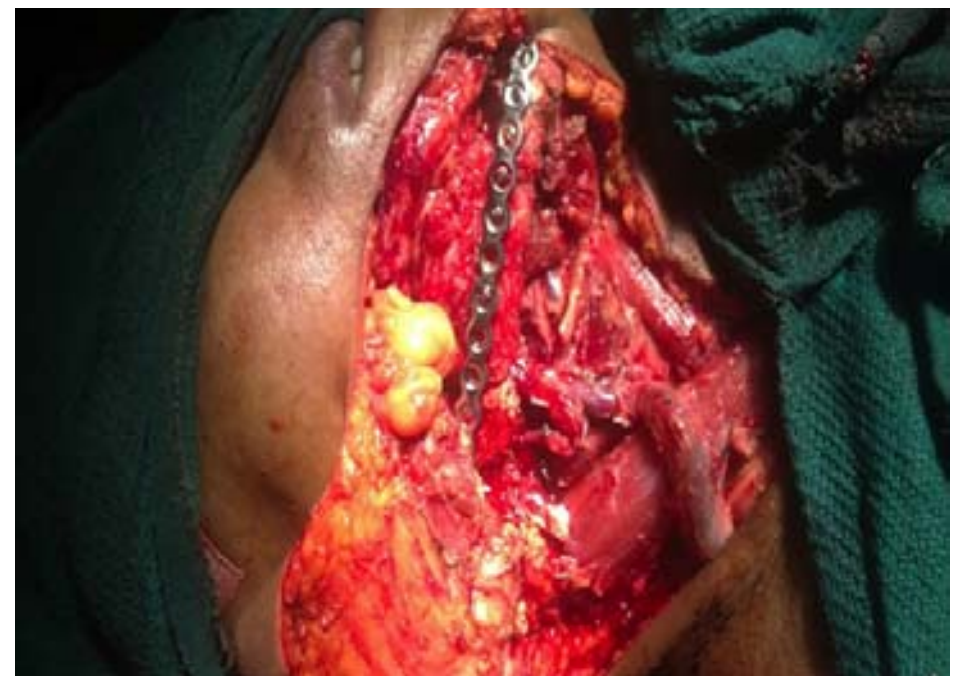

DATA

Free flaps	Defects	Pathology	Average age and sex ratio M:F	2 months 10mm two point discrimi nation	6 months two point discrimi nation	Recipient nerves	Donor nerve
Radial forearm flaps(16)	cheek(10) Tongue(4) Soft palate(2)	Post excisional(16)	62 9:7	45%	78%	Sensory buccal nerve(12) & Lingual nerves(4)	Lateral cut nerve(10) or sensory sup br of radial nerve(6)
Free fibula osteo cut flap(26)	Maxilla(3) Mandible (23)	Post excisional (23)post trauma(3)	55 24:2	40%	70%	Sensory buccal(10) Greater auricular(16)	Superficial peroneal nerve in all cases

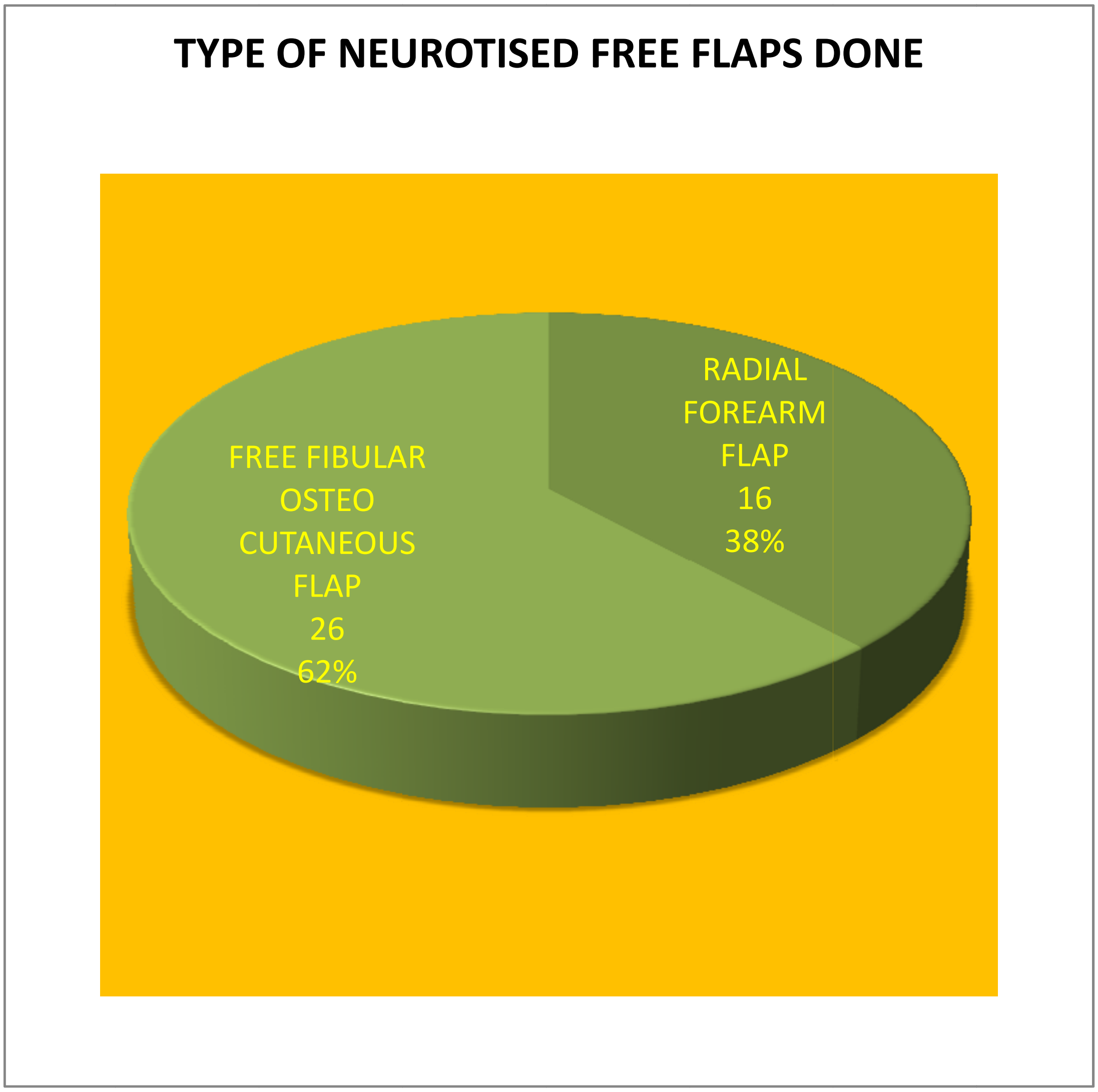
TYPE OF NEUROTISED FREE FLAPS DONE
RADIAL FOREARM FLAP 16 38%
FREE FIBULAR OSTEO CUTANEOUS FLAP 26 62%

NUMBER OF RADIAL FOREARM FLAPS FOR FOLLOWING DEFECTS

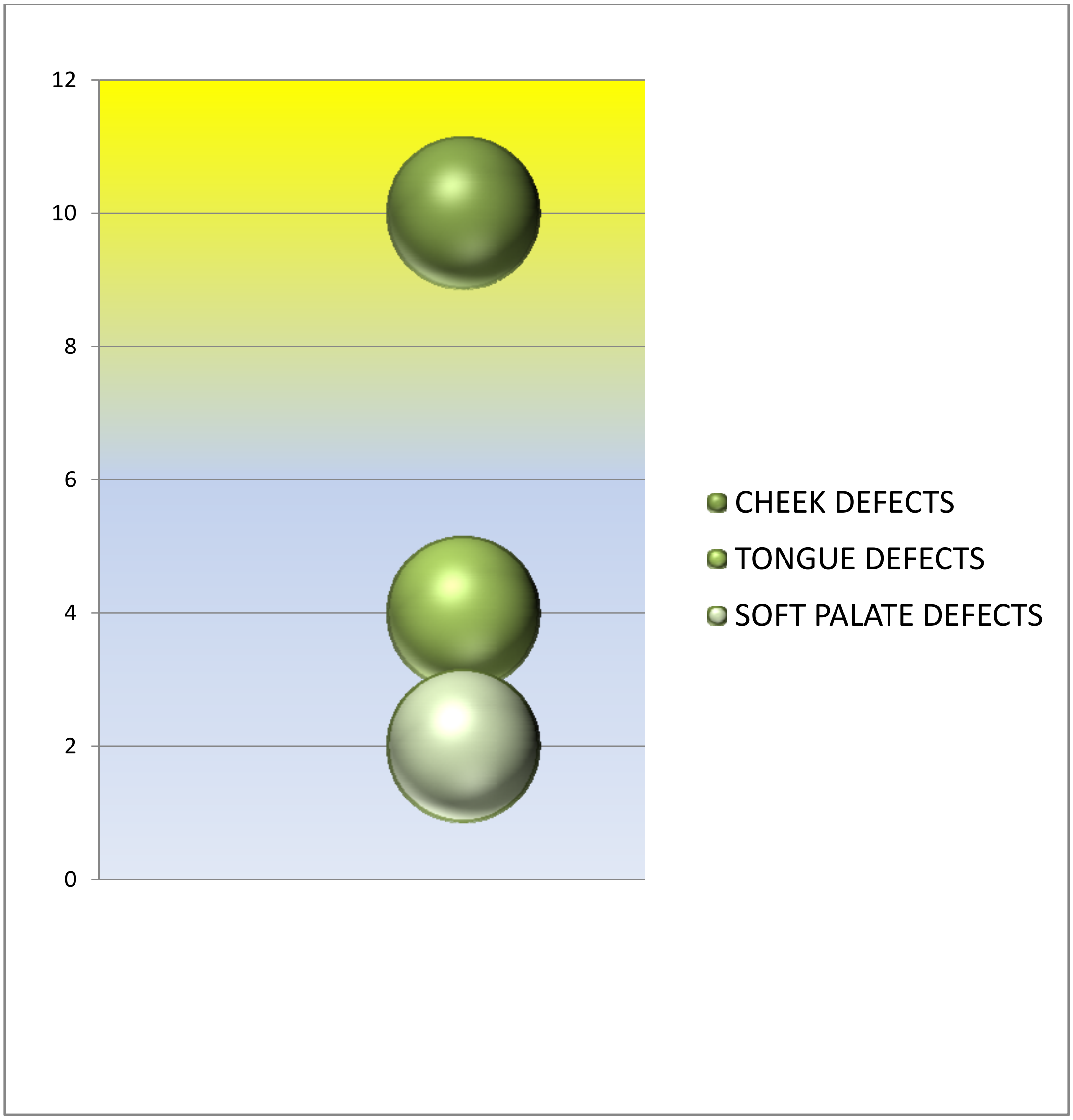

FREE FIBULAR FLAPS

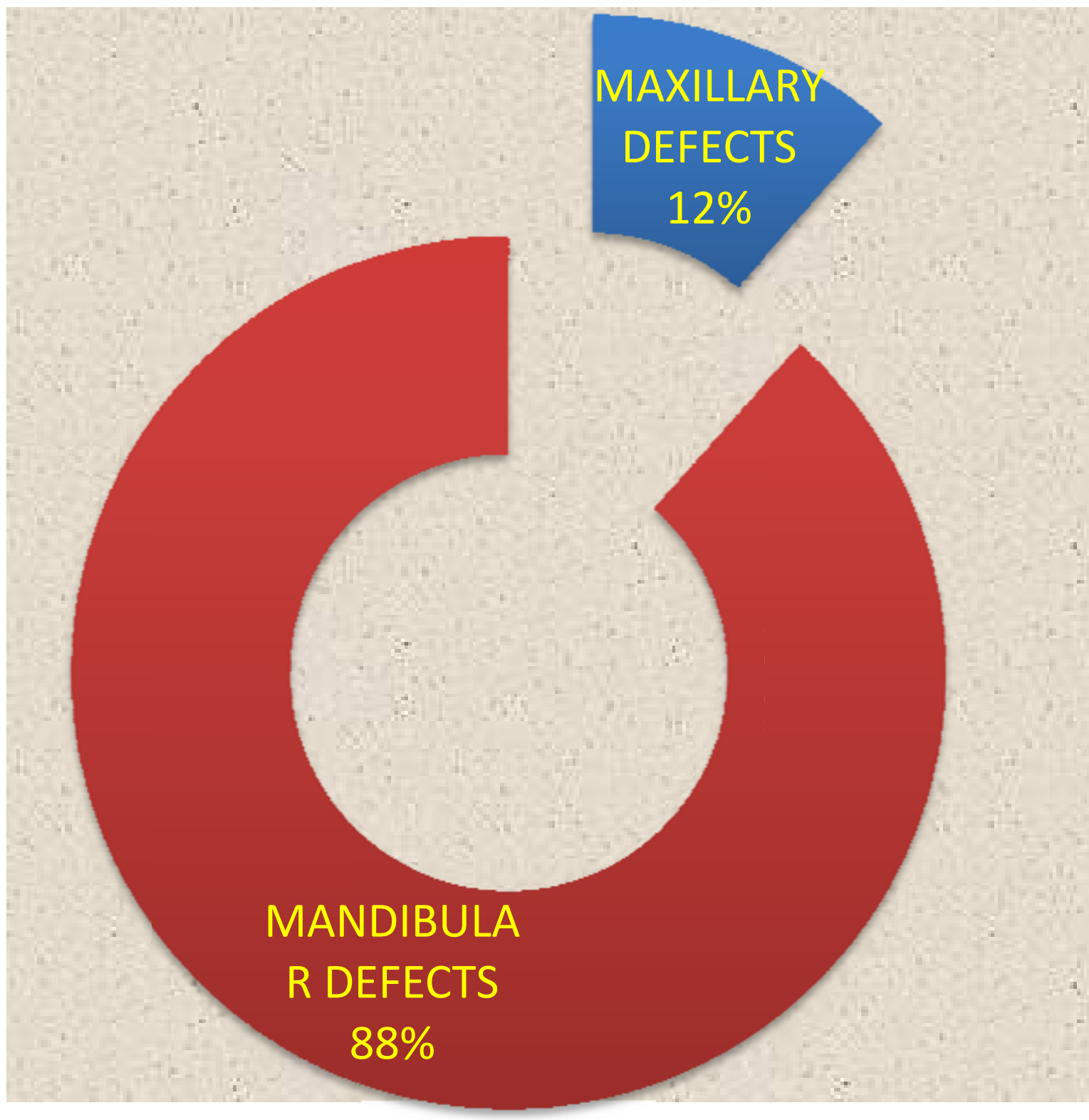

ETIO PATHOLOGY OF THE DEFECT

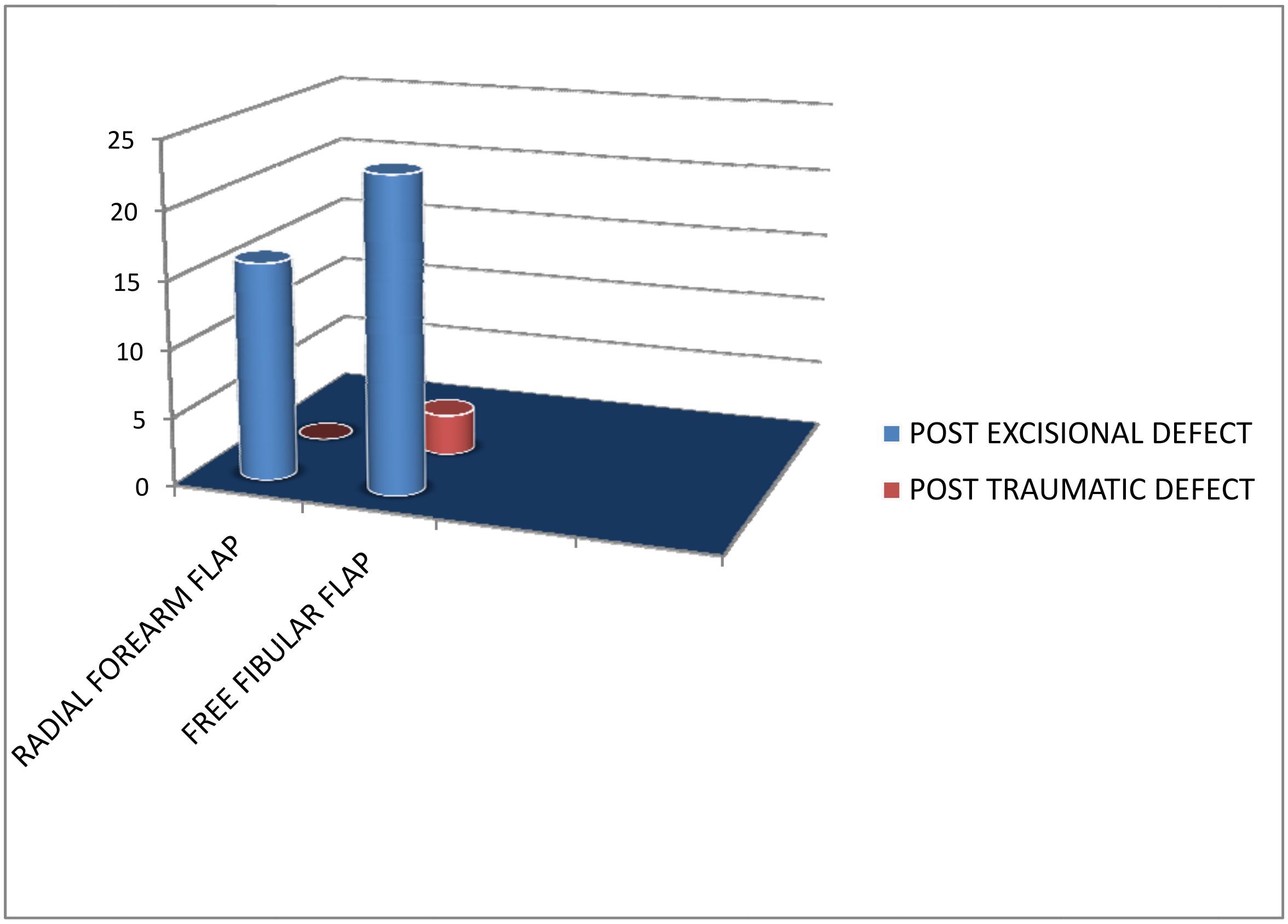

SEX RATIO OF FLAPS

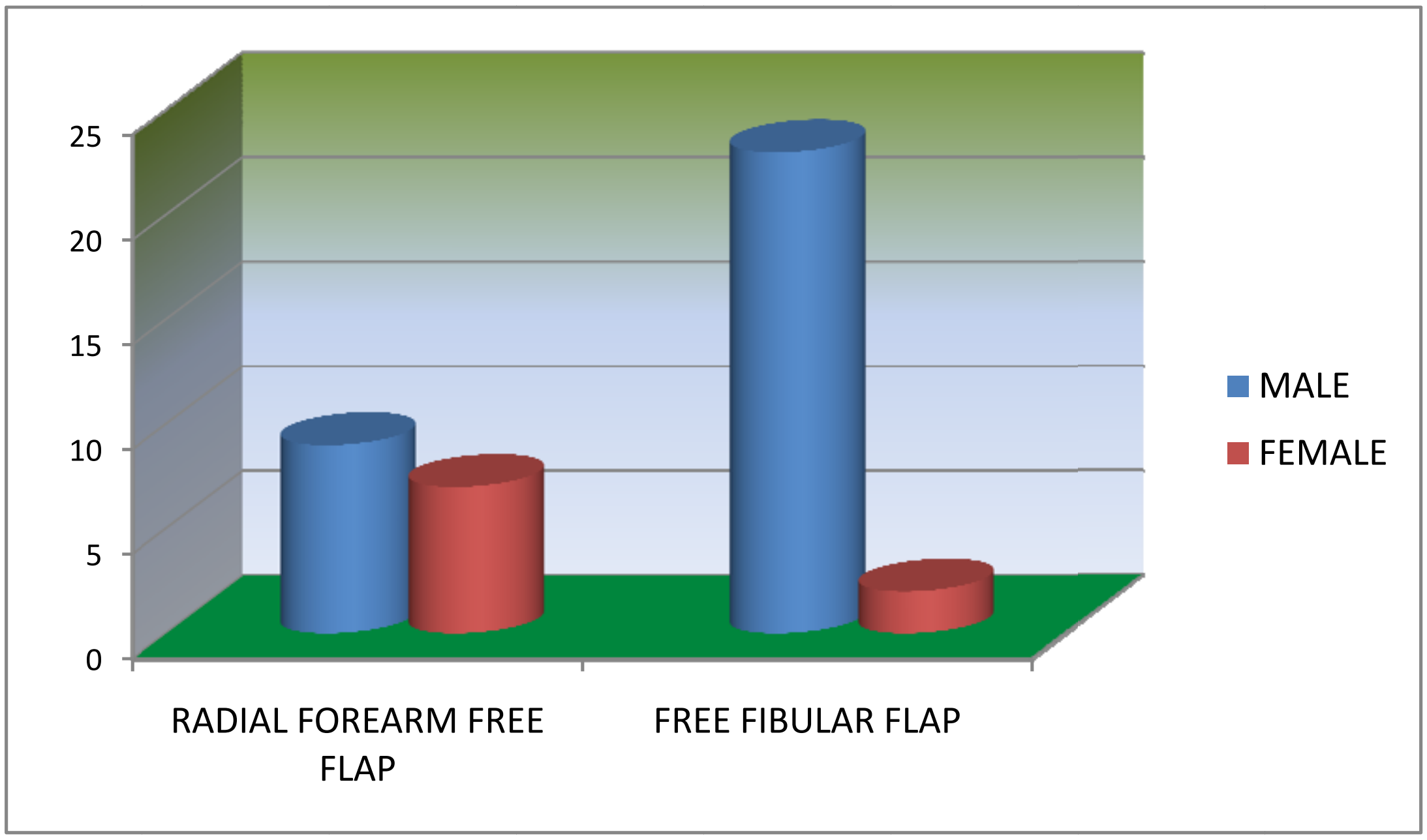

RECIPIENT NERVES RADIAL FOREARM FLAP

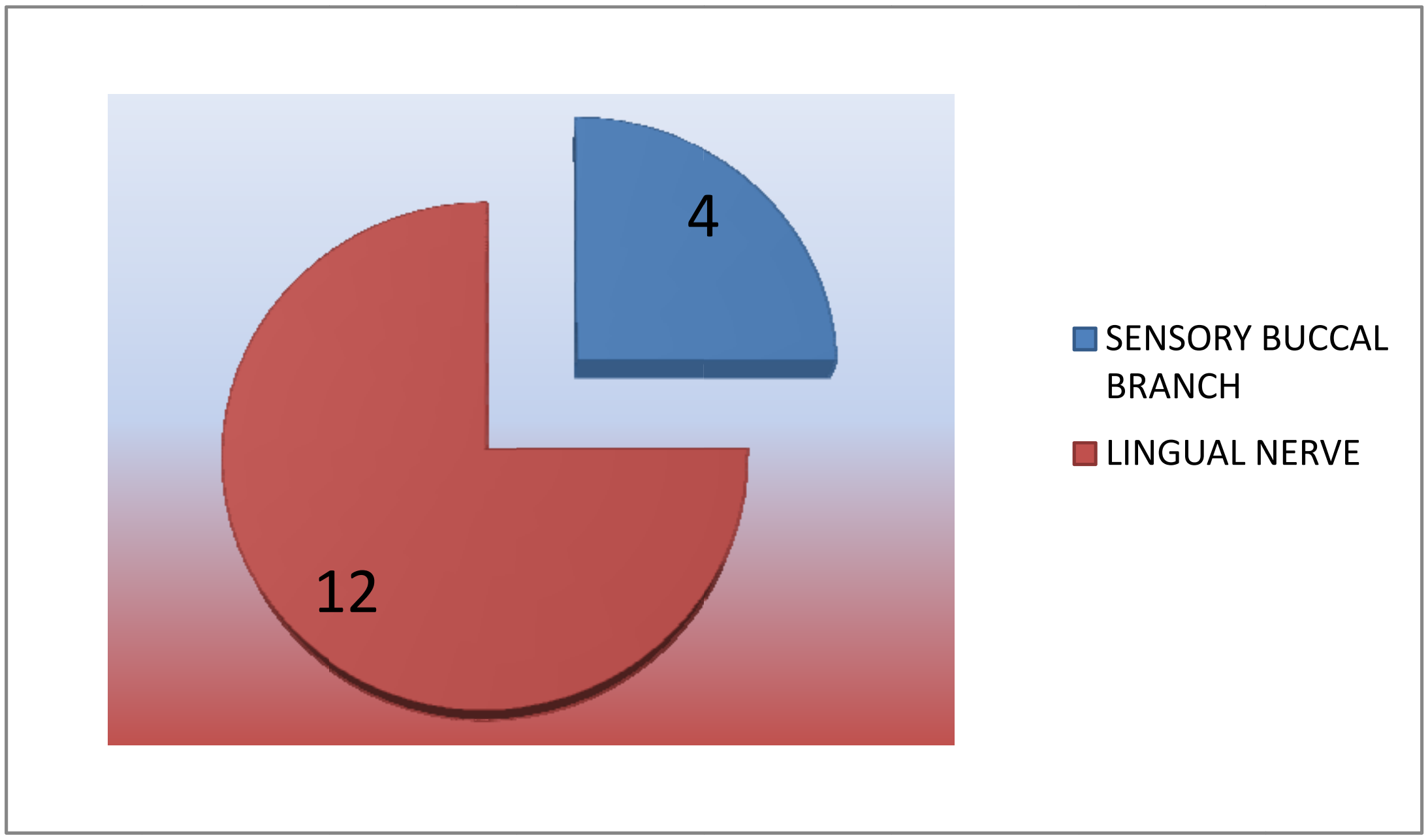

DONOR NERVES IN RADIAL FOREARM FLAP

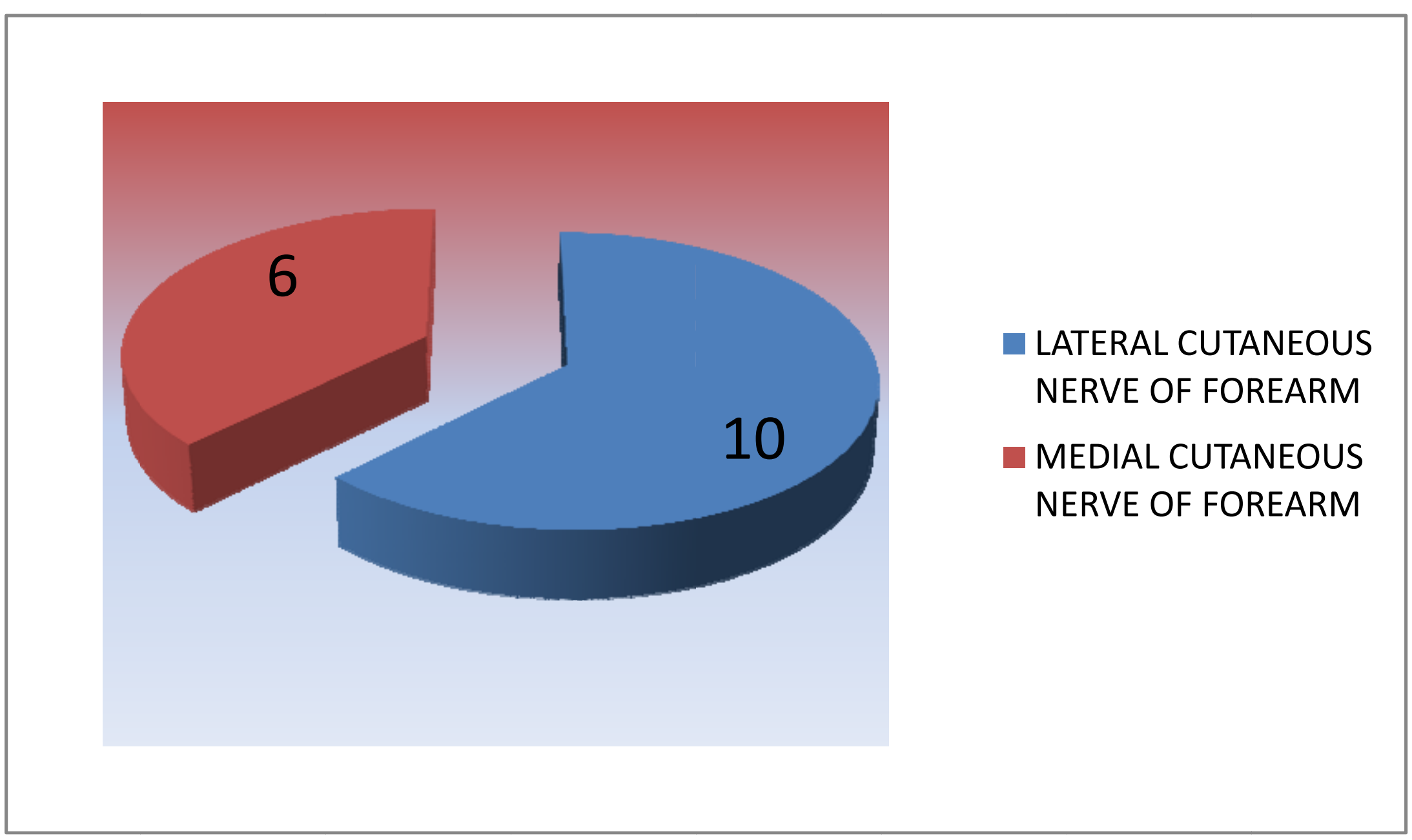

RECIPIENT NERVES FOR FREE FIBULAR FLAP

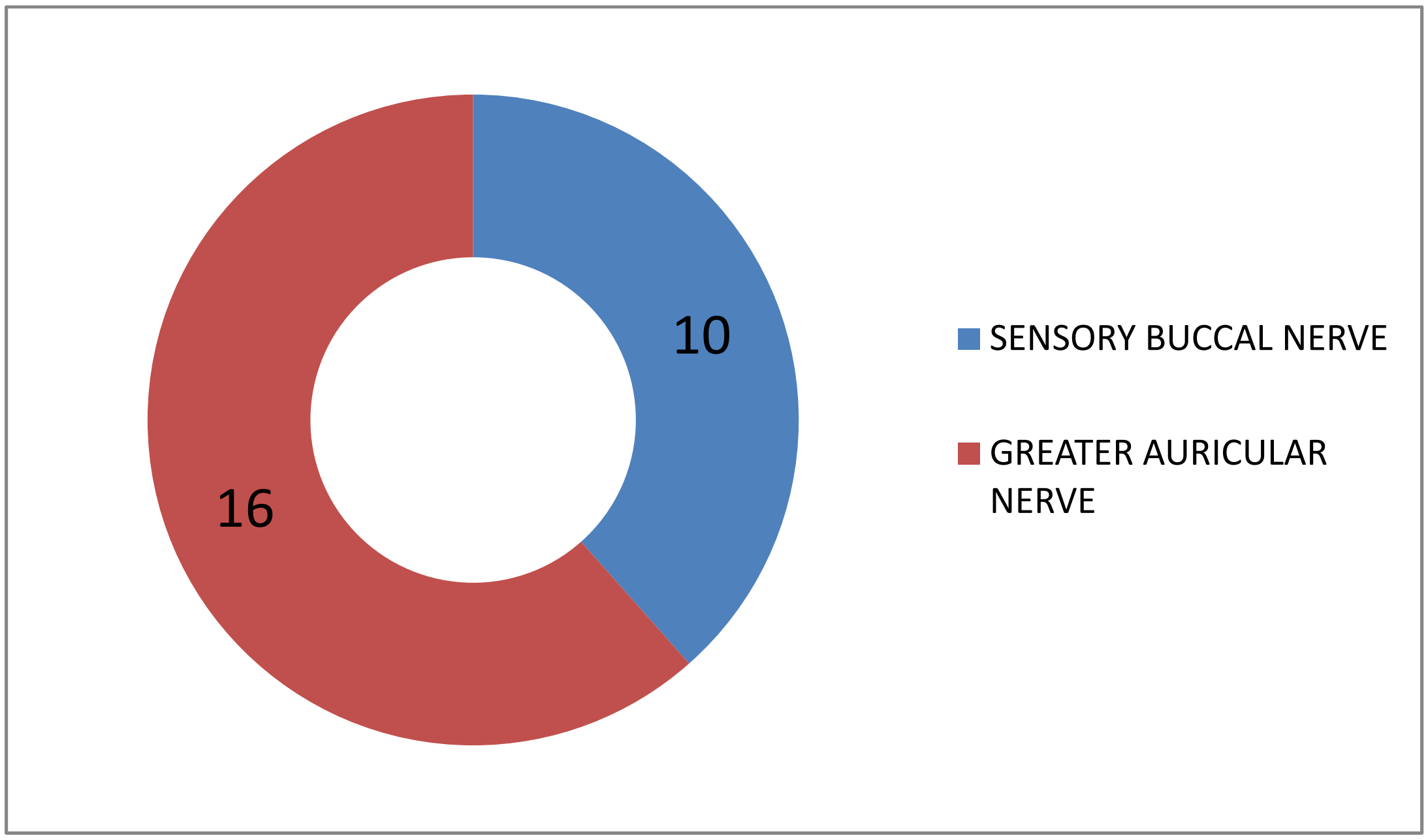

DONOR NERVE IN FREE FIBULAR FLAP

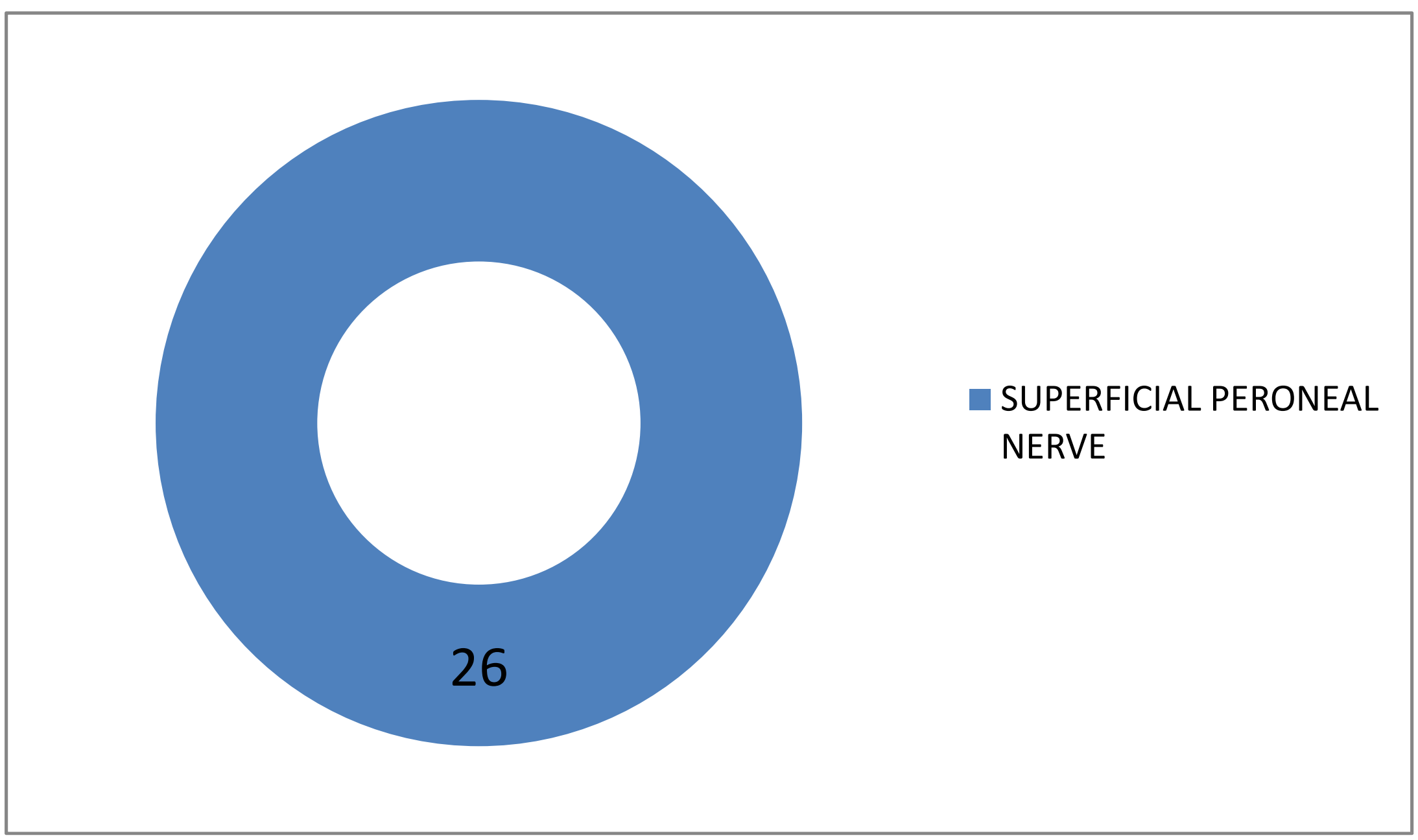

10 mm TWO POINT DICRIMINATION

RADIAL FOREARM FLAP

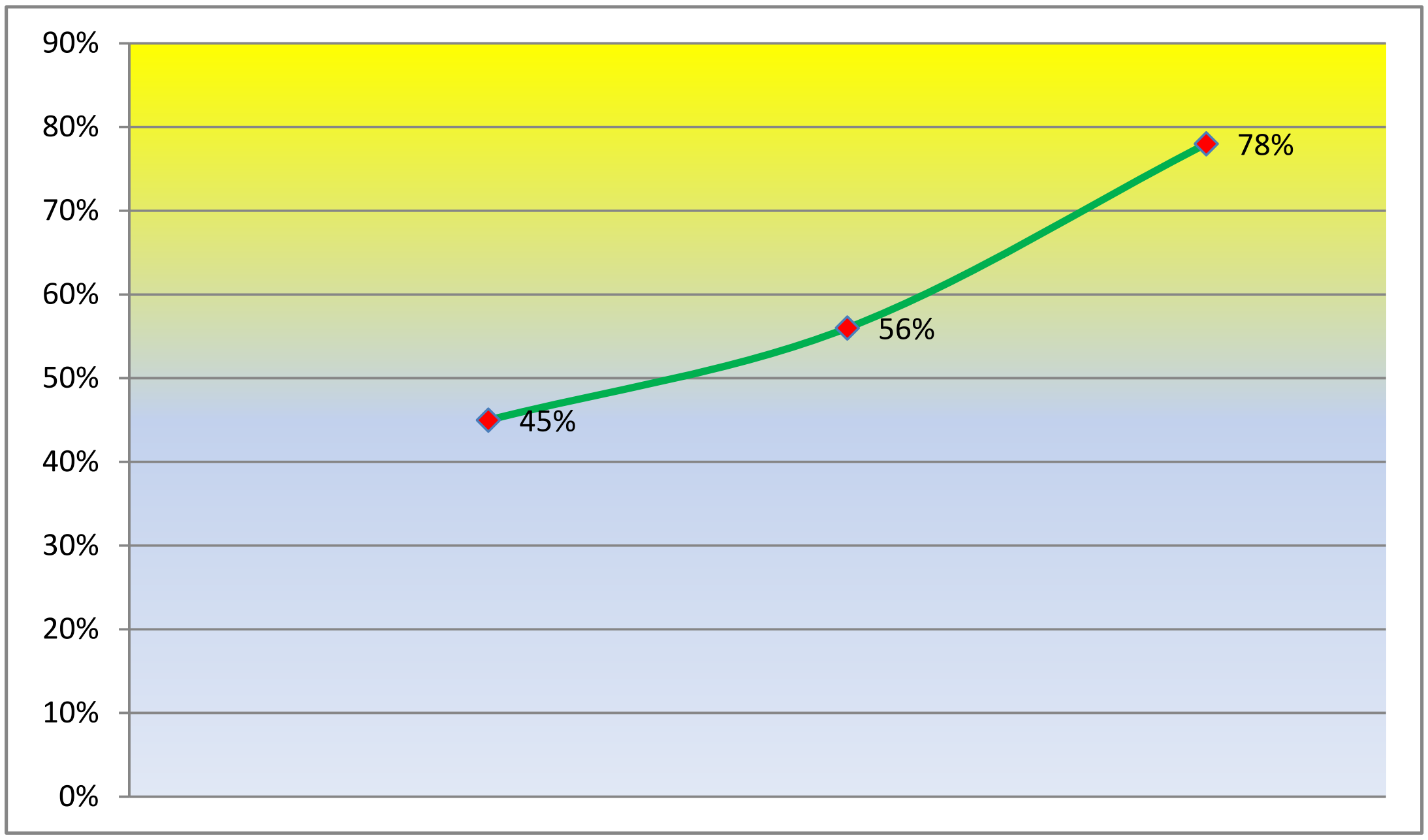

FREE FIBULAR FLAP

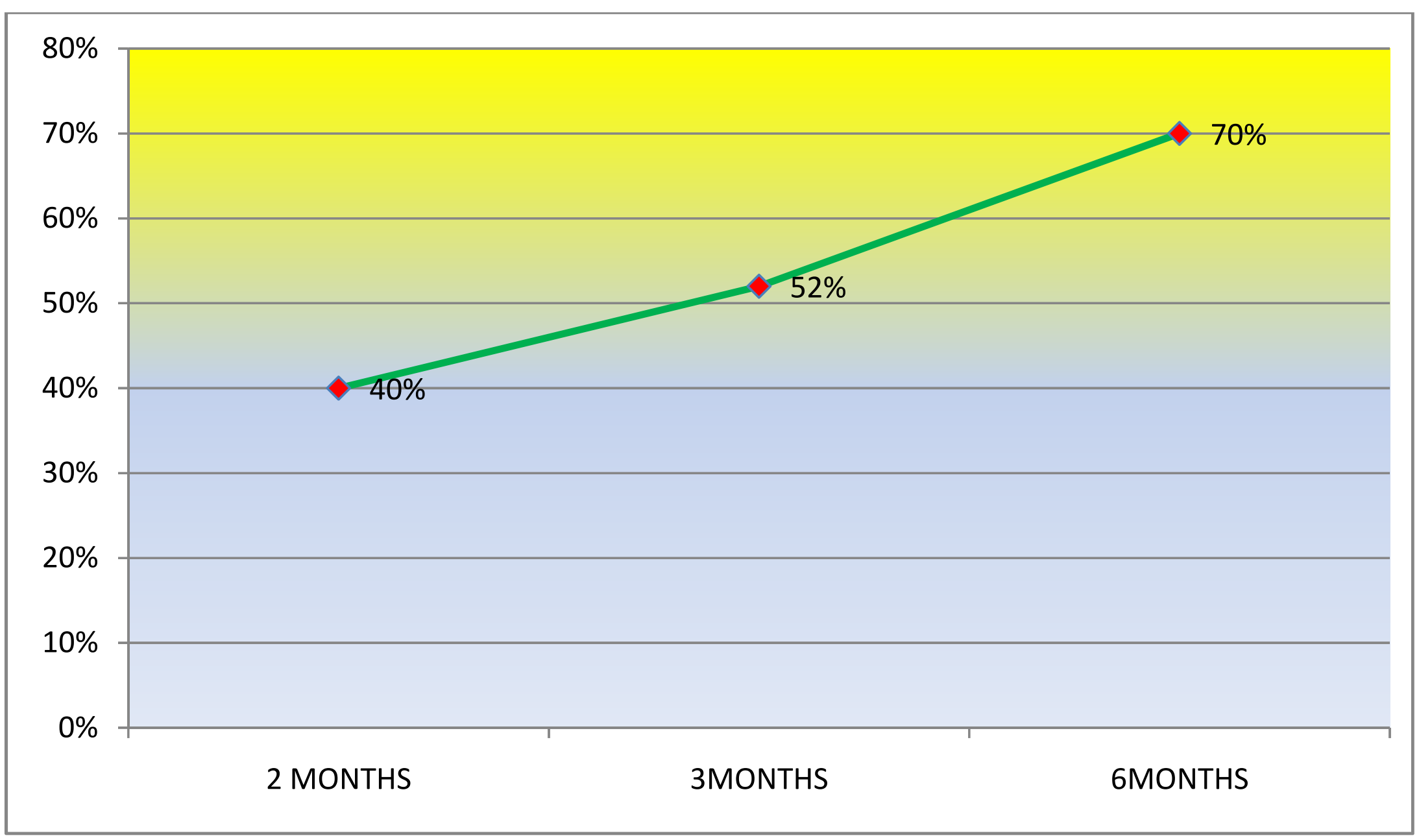

RESULTS

Dexterity in swallowing, mastication, and speech function necessitates good sensory feedback. When insensate free flaps were used for lining in the cheek, tongue, and soft palate areas, absence of sensory feed back or absence of proprioception from insensate areas prevent the coordinated, dexterous, functions of upper aero digestive tract. Speech, mastication and swallowing necessitate close coordination between sensory and motor pathway of the nervous system. A neurotised flap goes long way in bringing the proprioception and necessary sensory feedback into the post oncological resection areas. Thereby early recovery of upper aero digestive tract functions are expected to happen.

This is our hypothesis which has been confirmed by the clinical study.

Recipient nerves like lingual nerve for the tongue reconstruction, greater auricular nerve fascicle for the floor of mouth reconstruction and sensory buccal branch of mandibular division of trigeminal nerve for mandibular reconstruction.

The recipient nerves are prepared simultaneously along with the blood vessels. Neural anastomosis is done as a last step following arterio venous anastomosis using 9-0 Prolene or Ethilon with micro tipped needle under magnification.

The relevant upper aero digestive functions are expected to be absent immediately following oncological resection. Reconstruction is specifically followed with recovery of sensation at specific intervals.

For example in soft palate reconstruction, radial forearm flap is harvested along with lateral cutaeous nerve of forearm and it is coapted with sensory buccal branch of mandibular division of trigeminal nerve. So immediately after reconstruction , there is nasal speech, regurgitation during swallowing likely to happen. With the Ryles tube feeding, quality of speech and recovery of sensation in reconstructed flap are closely observed.

Since we use Palmaris longus tendon is used for reconstruction of levator sling, though the soft tissue elevation occurs immediately after resection, there is always nasal speech which is again supporting point for our hypothesis.

With the good two point discrimination recovery, patient speech improves well. Trial swallowing with the Ryle’s tube for solids and liquids is also tested and found to be one mouth early recovery for swallowing function than for speech.

This may be related to the need for more sensory input for the speech which is a higher motor function rather than swallowing which is the function of brain stem.

TONGUE RECONSTRUCTION:

In the tongue, after the resection in all subtotal / total glossectomies, reconstruction is done with radial forearm flap with lateral cutaneous nerve of forearm anastomosed to lingual nerve, after vascular anastomosis. In these patients, speech with reference to fricatives, linguals, and labials are assessed. The swallowing is also concurrently assessed. What is also noted in these cases, is the entrapment of the flap in the remaining teeth during mastication. What we noticed in these patients with good recovery in two point discrimination which happens by average of 2.5 months, there is early recovery in the swallowing dexterity with the lead of 21 days, where we remove the Ryle's tube and ask them to swallow the liquids and solids. Even without thinning of flap, the entrapment and ulceration of the flap by the remaining teeth during mastication are nil in our series.

CHEEK RECONSTRUCTION:

In the cheek reconstruction also lateral/medial cutaneous nerve of forearm is anastomosed to the sensory buccal nerve of trigeminal nerve. Here also, speech, swallowing, and the entrapment of the flap by the teeth are assessed. There is early recovery of speech, swallowing. Also there is no report of entrapment of the flap in the clinical series.

MAXILLA RECONSTRUCTION:

We have done fibula osteo cutaneous free flap for maxilla reconstruction, superficial peroneal nerve is anastomosed with sensory buccal branch of trigeminal nerve.

Here also, we are assessing the recovery of speech and swallowing.

MANDIBULAR RECONSTRUCTION:

We excluded the cases where lip is excised or where orbicularis oris muscle can’t be reconstituted. Neurotisation of the free fibular flap is done by coapting superficial peroneal nerve with the recipient nerve. In these cases, stasis of food in sulcal area doesn’t occur specifically, with the good recovery of two point discrimination.

ANALYSIS AND DISCUSSION

Mucosal sensation has a vital impact on oral function and quality of life. The role of sensation in the oral cavity includes oral continence, preventing pooling of saliva, mastication, food bolus sweep to the oropharynx, and oral hygiene.

On comparing the functional recovery of neurotised flaps with the non neurotised flaps, the following findings observed with significant P-value in student's chi square test.

a. Neurotised free flaps were superior to non neurotised free flaps in every modality tested

b. 75% of neurotised flaps could distinguish a sharp pain from blunt pressure, compared with 10% of the non-neurotised ones all neurotised flaps could detect hot and cold while only 50% of non-neurotised flaps detected hot

c. Two-point discrimination was of an extremely high order in all patients with neurotised flaps, but essentially nonexistent in those with non-neurotised flaps

d. Sensation in the neurotised flaps was essentially equal to that of the contralateral tongue at a mean follow-up of only 11 months.

e. The comparison of the neurotised flaps with their own donor sites (detecting pain, hot and cold, and two-point discrimination) revealed the nonoperated forearms were significantly inferior to the results achieved by the contralateral forearms when neurotised by the lingual nerve

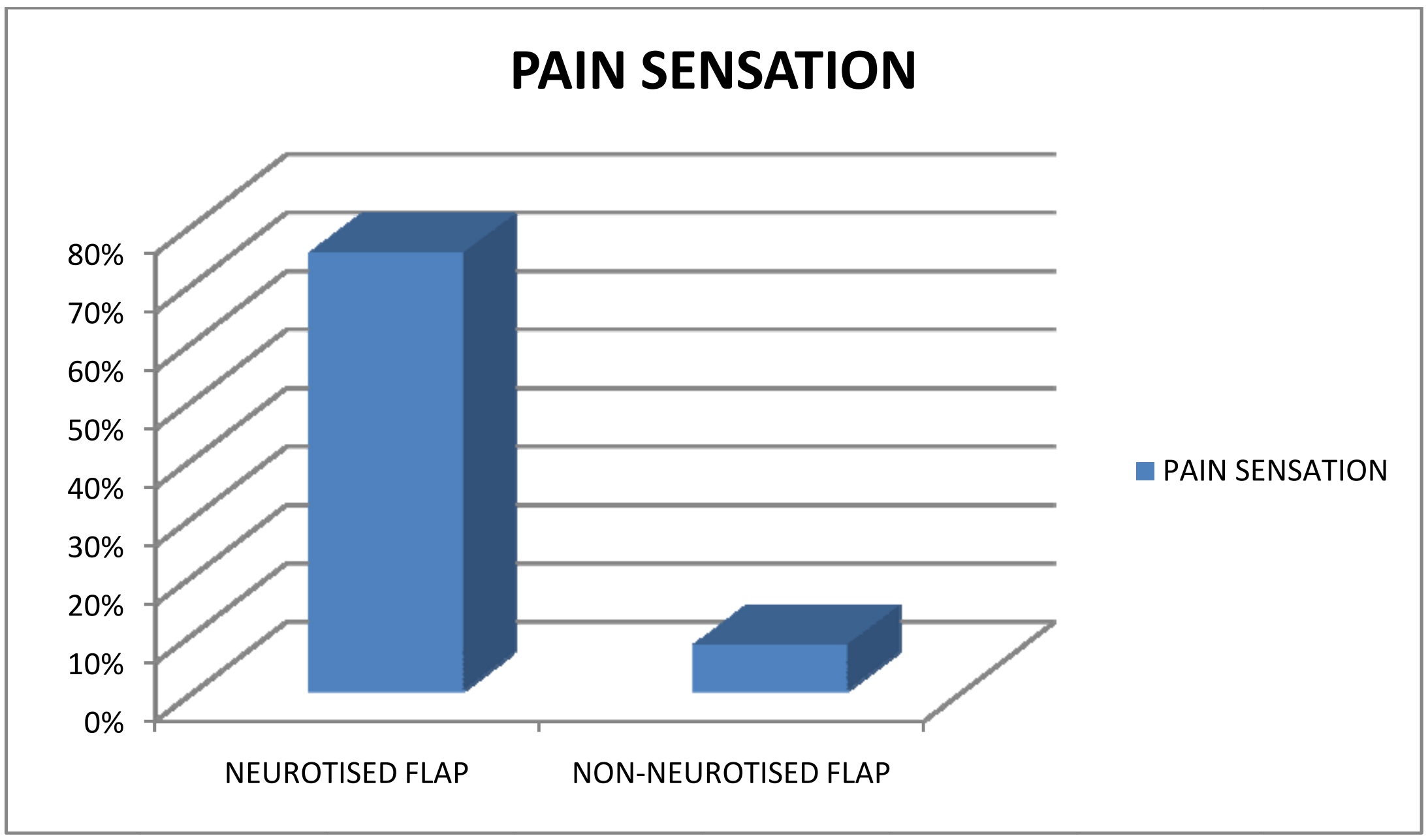

P-Value by student’s chi square test = 0.0001

Extremely significant

HOT AND COLD SENSATION

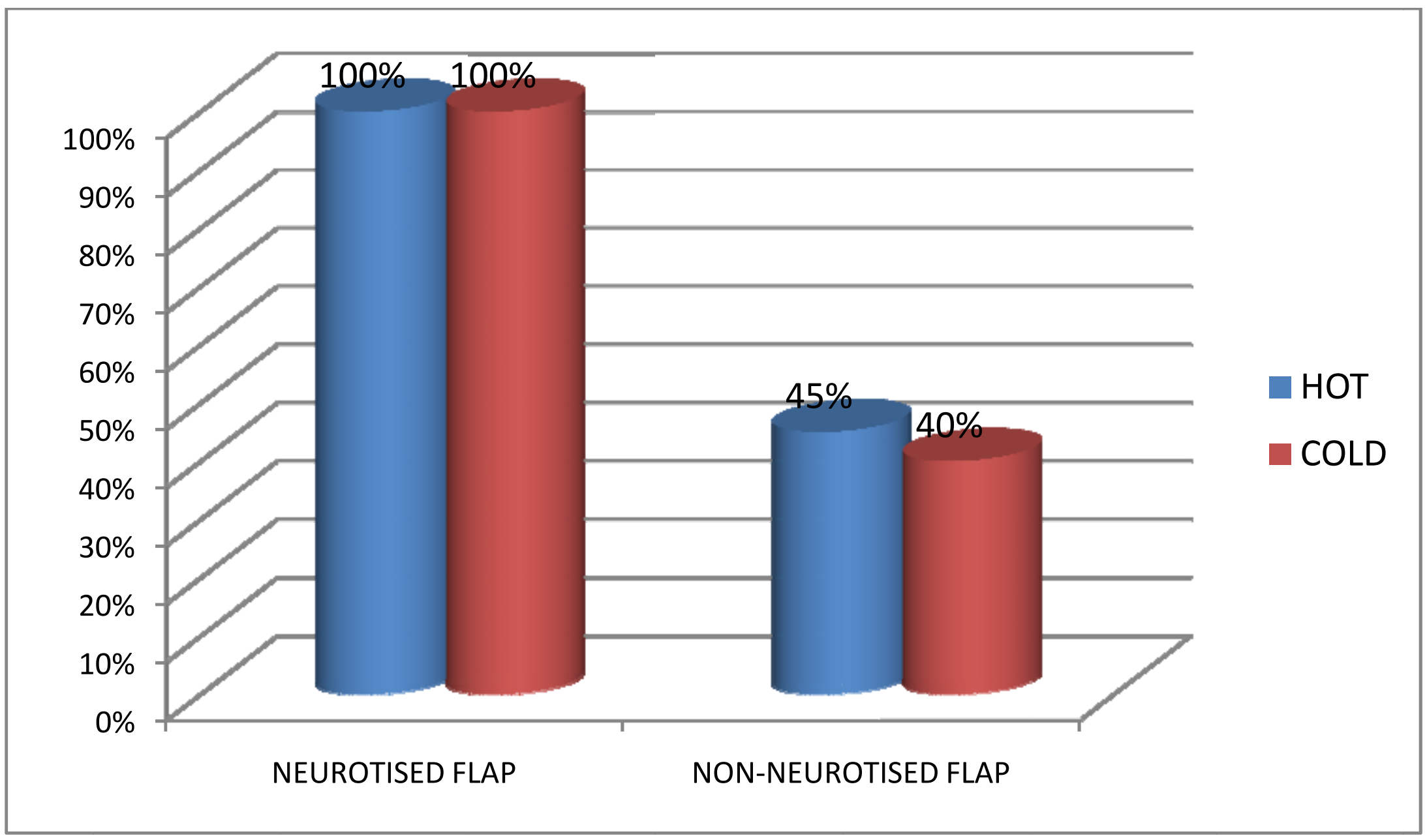

P-Value for hot sensation = 0.0018

P-Value for cold sensation = 0.0007. Both P-Values are extremely significant.

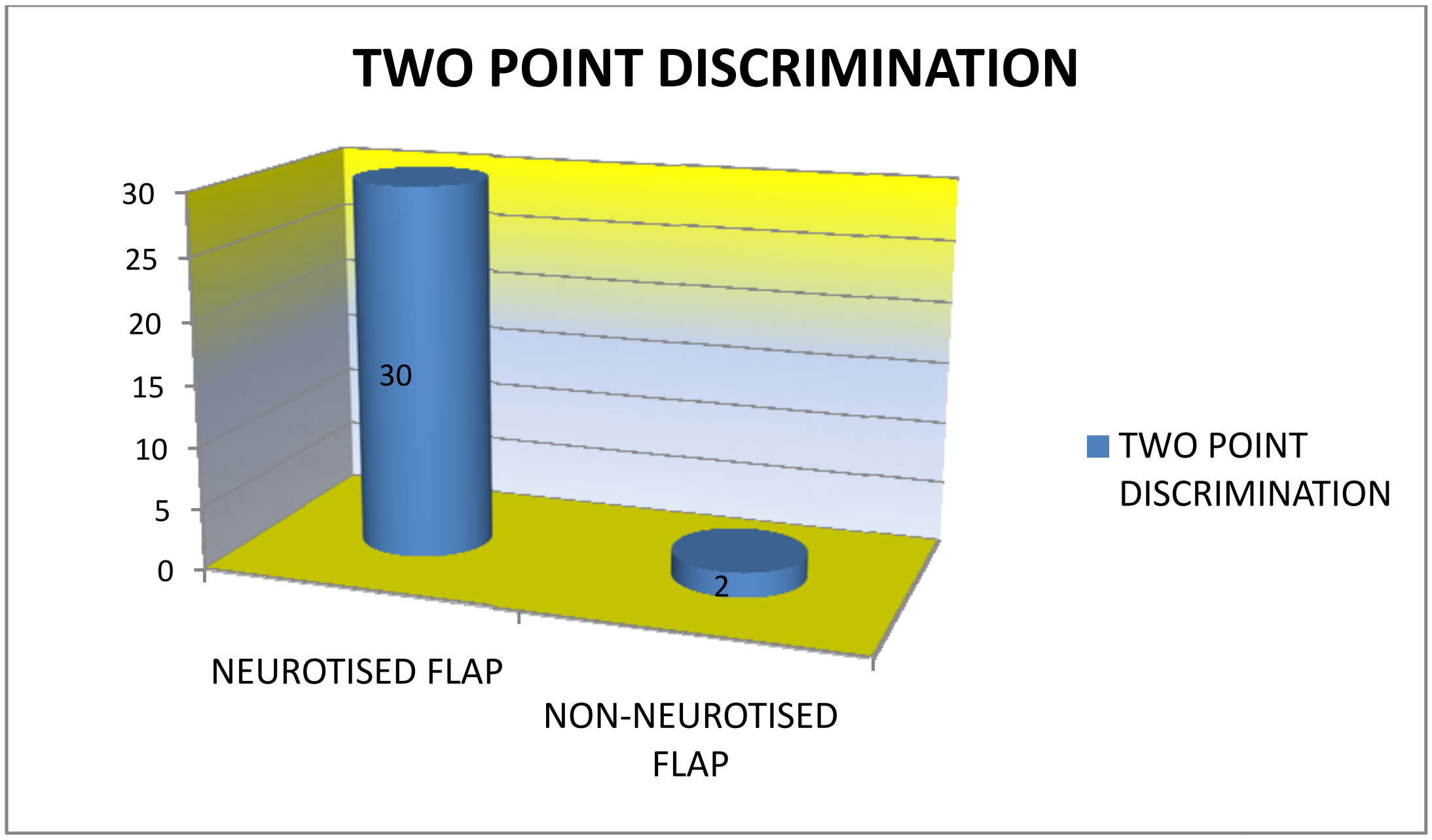
TWO POINT DISCRIMINATION
30
25
20
15
10
5
0
30
2
NEUROTISED FLAP
NON-NEUROTISED FLAP
TWO POINT DISCRIMINATION

The case in which superficial peroneal nerve is anastomosed with sensory buccal nerve using the avascular sural nerve graft showed lag in recovery of upper aero digestive functions – again supporting our hypothesis that direct neurorrhaphy with single anastomosis . Where in single anastomosis, after lag of 28 days, sensory axons easily pass through the single anastomotic site to reach the effector organ.

Where in graft is used, axons have to pass through two anastomotic sites. So there is poor recovery in two point discrimination and delayed recovery of upper aero digestive functions.

SUMMARY AND CONCLUSION

Direct neurorrhaphy between the vascularised donor nerve harvested along with the free flap and recipient nerve,with single anastomosis pave the way for the early sensory recovery. We recommend this a small step ahead which brings in good functional dexterity in most of the upper aero digestive functions.

The functional recovery is not only directly related to proprioceptive recovery in the reconstructed flap but also simultaneous reconstitution of motor organs like levator sling and orbicularis oris reconstitution.

The ultimate aim in plastic and reconstructive surgery is to re-establish form and function. So, the small step of direct neurotisation of the free flaps is not only re-establish the local form, but also early good function.

BIBLIOGRAPHY

1. Crile G: Excision of cancer of the head and neck. With special reference to the plan of dissection based on one hundred and thirty-two operations. *JAMA 47:1780, 1906. (Reprinted in JAMA 258:3286, 1987.)*
2. Edgerton MT Jr: Replacement of lining to oral cavity following surgery. *Cancer 4:110, 1951.*
3. McGregor IA: Temporal flap in intraoral cancer: its use in repairing the post-excisional defect. *Br J Plast Surg 16:318, 1963.*
4. Bakamjian VY: A two-stage method for pharyngoesophageal reconstruction with a primary pectoral skin flap. *Plast Reconstr Surg 36:173, 1965.*
5. Ariyan S: The pectoralis major myocutaneous flap: a versatile flap for reconstruction in the head and neck. *Plast Reconstr Surg 63:73, 1979.*
6. Urken ML, Chaney ML, Sullivan MJ, Billar HF: *Atlas of Regional and Free Flaps for Head and Neck Reconstruction. New York, Raven Press, 1995, Ch 1.*
7. Quillen CG, Shearin JC Jr, Georgiade NG: Use of the latissimus dorsi myocutaneous island flap for reconstruction in the head and neck area. *Plast Reconstr Surg 62:113, 1978.*

8. Quillen CG: Latissimus dorsi myocutaneous flaps in head and neck reconstruction. *Plast Reconstr Surg 63:664, 1979.*
9. McCraw JB, Dibbell DG: Experimental definition of independent myocutaneous vascular territories. *Plast Reconstr Surg 60:212, 1977.*
10. Conley J: Use of composite flaps containing bone for major repairs in the head and neck. *Plast Reconstr Surg 49:522, 1972.*
11. Shestak KC, Matloub HS: Oral cavity reconstruction. *Cancer Bull 42:25, 1990.*
12. Shestak KC, Jones NF, Wu W, et al: The effect of advanced stage and medical disease on the outcome of microvascular reconstruction for head and neck defects. *Head Neck 14:14, 1992.*
13. Markowitz B, Calcaterra TC: Preoperative assessment and surgical planning for patients undergoing immediate composite reconstruction of oromandibular defects. *Clin Plast Surg 21(1):9, 1994.*
14. Shestak KC, Myers EN, Ramasastry SS, et al: Vascularized free-tissue transfer in head and neck surgery. *Am J Otolaryngol 14(3):148, 1993.*
15. Sharzer LA et al: Intraoral reconstruction in head and neck cancer surgery. *Clin Plast Surg 3(3):495, 1976.*

16. Schramm VL, Myers EN: Skin grafts in oral cavity reconstruction. *Arch Otolaryngol 106:528, 1980.*

17. Bradley P, Brockbank J: The temporalis muscle flap in oral reconstruction. *J Maxillofac Surg 9:139, 1981.*

18. Clauser L, Curioni C, Spanio S: The use of the temporalis muscle flap in facial and craniofacial reconstructive surgery. A review of 182 cases. *J Craniomaxillofac Surg 23:203, 1995*.

19. Thomson CJ, Allison RS: The temporalis muscle flap in intraoral reconstruction. *Aust N Z J Surg 67:878, 1997.*

20. McGregor IA, Jackson IT: The extended role of the deltopectoral flap. *Br J Plast Surg 23:173, 1970.*

21. Bakamjian VY, Long M, Rigg B: Experience with the medially based deltopectoral flap in reconstructive surgery of the head and neck. *Br J Plast Surg 24:174, 1971.*

22. Daniel RK, Cunningham DM, Taylor GI: The deltopectoral flap: an anatomical and hemodynamic approach. *Plast Reconstr Surg 55:275, 1975.*

23. Park JS, Sako K, Marchetta FC: Reconstructive experience with the medially based deltopectoral flap. *Am J Surg 128:548, 1974.*

24. Ariyan S, Cuono CB: Myocutaneous flaps for head and neck reconstruction. *Head Neck Surg 2:321, 1980.*

25. Mathes S, Nahai F: ***Clinical Applications for Muscle and Musculocutaneous Flaps.*** *St Louis, CV Mosby, 1991. SRPS Volume 9, Number 10*

26. Ariyan S: Further experiences with the pectoralis major myocutaneous flap for the immediate repair of defects from excisions of head and neck cancers. *Plast Reconstr Surg 64:605, 1979.*

27. Baek S-M, Lawson W, Biller HF: An analysis of 133 pectoralis major myocutaneous flaps. *Plast Reconstr Surg 69:460, 1982.*

28. McGregor IA: Fasciocutaneous flaps in intraoral reconstruction. *Clin Plast Surg 12:453, 1985.*

29. Matthews RN et al: Radial forearm flap for floor of mouth reconstruction. *Br J Surg 72:561, 1985.*

30. Soutar DS, McGregor IA: The radial forearm flap in intraoral reconstruction: the experience of 60 consecutive cases. *Plast Reconstr Surg 78:1, 1986.*

31. Takato T et al: Oral and pharyngeal reconstruction using the free forearm flap. *Arch Otolaryngol Head Neck Surg 113:873, 1987.*

32. Anthony JP, Neligan PC, Rotstein LE, Coleman J: Reconstruction of partial laryngopharyngectomy defects. *Head Neck 19:541, 1997*.

33. Stark B, Nathanson A, Heden P, Jernbeck J: Results after resection of intraoral cancer and reconstruction with the free radial forearm flap. *ORL J Otorhinolaryngol Relat Spec 60:212, 1998.*

34. Moscoso JF, Urken ML: Radial forearm flaps. *Otolaryngol Clin North Am 27(6):1119, 1994.*

35. Hermanson A, Dalsgaard CJ, Arnander C, Lindblum U: Sensibility and cutaneous reinnervation in free flaps. *Plast Reconstr Surg 79:422, 1987.*

36. Hayden RE: Free flap transfer for restoration of sensation and lubrication to the reconstructed oral cavity and pharynx. *Otolaryngol Clin North Am 27(6):1185, 1994.*

37. Boyd B et al: Reinnervated lateral antebrachial cutaneous neurosome flaps in oral reconstruction: Are we making sense? *Plast Reconstr Surg 93:1350, 1994.*

38. Cordeiro PG, Schwartz M, Neves RI, Tuma R: A comparison of donor and recipient site sensation in free tissue reconstruction of the oral cavity. *Ann Plast Surg 39:461, 1997.*

39. Urken ML et al: Oromandibular reconstruction using microvascular composite free flaps. Report of 71 cases and a new classification scheme for bony, soft-tissue, and neurologic defects. *Arch Otolaryngol Head Neck Surg 117:733, 1991.*

40. Graham B, Dellon AL: Sensory recovery in innervated freetissue transfers. *J Reconstr Microsurg 11:157, 1995.*

41. Dubner S, Heller KS: Reinnervated radial forearm flaps in head and neck reconstruction. *J Reconstr Microsurg 8:467, 1992.*

43. Aguilar NV, Olson ML, Shedd DP: Rehabilitation of deglutition problems in patients with head and neck cancer. *Am J Surg 138:501, 1979.*

44. Schliephake H, Schmelzeisen R, Schonweiler R, et al: Speech, deglutition and life quality after intraoral tumour resection. A prospective study. *Int J Oral Maxillofac Surg 27:99, 1998.*

45. Konstantinovic VS, Dimic ND: Articulatory function and tongue mobility after surgery followed by radiotherapy for tongue and floor of the mouth cancer patients. *Br J Plast Surg 51:589, 1998.*

46. Knuuttila H, Pukander J, Maatta T, et al: Speech articulation after subtotal glossectomy and reconstruction with a myocutaneous flap. *Acta Otolaryngol 119:621, 1999.*

47. Cordeiro PG, Disa JJ, Hidalgo DA, Hu QY: Reconstruction of the mandible with osseous free flaps: a 10-year experience with 150 consecutive patients. *Plast Reconstr Surg 104:1314, 1999.*

48. Hidalgo DA: Fibula free flap: a new method of mandible reconstruction. *Plast Reconstr Surg 84:71, 1989.*

49. Hidalgo DA: Aesthetic improvements in free-flap mandible reconstruction. *Plast Reconstr Surg 88:574, 1991.*

50. Hidalgo DA, Rekow A: A review of 60 consecutive fibula free flap mandible reconstructions. *Plast Reconstr Surg 96:585, 1995*.

51. Schusterman MA, Reece GP, Miller MJ: The osteocutaneous fibula free flap: Is the skin paddle reliable? *Presented at the annual meeting of the American Association of Plastic Surgeons, San Antonio, Texas, 1991.*

52. Corrigan AM, O'Neill TJ: The use of the compound radial forearm flap in oro-mandibular reconstruction. *Br J Oral Maxillofac Surg 24:86, 1986.*

53. Muldowney JB, Leonard MS, Van Beek AL: Mandibular reconstruction using a free forearm flap. *Minn Med 70:505, 1987.*

54. Boyd JB et al: The iliac crest and the radial forearm flap in vascularized oromandibular reconstruction. *Am J Surg 159:301, 1990.*

55. Silverberg B, Banis JC Jr, Acland RD: Mandibular reconstruction with microvascular bone transfer. Series of 10 patients. *Am J Surg 150:440, 1985.*

SERIAL NO	PATIENT NAME	AGE/SEX	IP NO	DIAGNOSIS	RECONSTRUCTION DONE	DONOR NERVE	RECIPIENT NERVE	NEURORRHAPHY	SPEECH	SWALLOWING	MASTICATION	TWO POINT DISCRIMINATION AT 6 MONTHS	HOT AND COLD	PATIENT SATISFACTION	SURGEON SATISFACTION
1	CHELLAMMAL	60/F	53647	CA CHEEK	RADIAL FOREARM FLAP	LATERAL CUTANEOUS NERVE OF FOREARM	SENSORY BUCCAL BRANCH	DIRECT NEURORRHAPHY	GOOD	GOOD	SATISFACTORY	75%	EXCELLENT	GOOD	EXCELLENT
2	GANESAN	54/M	65347	CA SOFT PALATE	RADIAL FOREARM FLAP	LATERAL CUTANEOUS NERVE OF FOREARM	SENSORY BUCCAL BRANCH	DIRECT NEURORRHAPHY	GOOD	SATISFACTORY	GOOD	72%	EXCELLENT	GOOD	GOOD
3	GOMATHY	62/F	54368	CA TONGUE	RADIAL FOREARM FLAP	LATERAL CUTANEOUS NERVE OF FOREARM	LINGUAL NERVE	DIRECT NEURORRHAPHY	SATISFACTORY	GOOD	GOOD	68%	EXCELLENT	GOOD	GOOD
4	THANGAM	57/F	7865	CA CHEEK	RADIAL FOREARM FLAP	MEDIAL CUTANEOUS NERVE OF FOREARM	SENSORY BUCCAL BRANCH	DIRECT NEURORRHAPHY	GOOD	GOOD	GOOD	69%	EXCELLENT	GOOD	GOOD
5	DAVID	45/M	5463	CA CHEEK	RADIAL FOREARM	LATERAL CUTANEOUS NERVE OF FOREARM	SENSORY BUCCAL BRANC	DIRECT NEURORRHAPHY	GOOD	GOOD	GOOD	75%	EXCELLENT	GOOD	GOOD

			7		FLAP		H								
6	PONNAMMAL	68/F	56342	CA TONGUE	RADIAL FOREARM FLAP	LATERAL CUTANEOUS NERVE OF FOREARM	LINGUAL NERVE	DIRECT NEURORRHAPHY	SATISFACTORY	GOOD	GOOD	74%	EXCELLENT	GOOD	GOOD
7	RAJAM	66/F	54678	CA CHEEK	RADIAL FOREARM FLAP	LATERAL CUTANEOUS NERVE OF FOREARM	SENSORY BUCCAL BRANCH	DIRECT NEURORRHAPHY	GOOD	GOOD	GOOD	78%	EXCELLENT	GOOD	GOOD
8	JAYANTHI	67/F	56743	CA CHEEK	RADIAL FOREARM FLAP	MEDIAL CUTANEOUS NERVE OF FOREARM	SENSORY BUCCAL BRANCH	DIRECT NEURORRHAPHY	GOOD	GOOD	GOOD	74%	EXCELLENT	GOOD	GOOD
9	RAJENDRAN	48/M	8769	CA TONGUE	RADIAL FOREARM FLAP	MEDIAL CUTANEOUS NERVE OF FOREARM	LINGUAL NERVE	DIRECT NEURORRHAPHY	GOOD	GOOD	GOOD	78%	EXCELLENT	GOOD	EXCELLENT
10	DEVI	60/M	4536	CA CHEEK	RADIAL FOREARM FLAP	LATERAL CUTANEOUS NERVE OF FOREARM	SENSORY BUCCAL BRANCH	DIRECT NEURORRHAPHY	GOOD	GOOD	GOOD	68%	EXCELLENT	GOOD	GOOD
11	KANNIAH	64/M	7685	CA CHEEK	RADIAL FOREARM FLAP	MEDIAL CUTANEOUS NERVE OF FOREARM	SENSORY BUCCAL BRANCH	DIRECT NEURORRHAPHY	GOOD	GOOD	GOOD	80%	EXCELLENT	GOOD	GOOD
12	PONGAN	62/M	654	CA CHEEK	RADIAL FOREA	LATERAL CUTANEOUS NERVE OF	SENSORY BUCCAL	DIRECT NEURORRHAPHY	GOOD	EXCELLENT	GOOD	68%	EXCELLENT	GOOD	GOOD

			7		RM FLAP	FOREARM	BRANCH								
13	GOVINDHAN	59/m	6534	CA SOFT PALATE	RADIAL FOREARM FLAP	MEDIAL CUTANEOUS NERVE OF FOREARM	SENSORY BUCCAL BRANCH	DIRECT NEURORRHAPHY	GOOD	GOOD	GOOD	67%	EXCELLENT	GOOD	GOOD
14	RAMACHANDRAN	48/M	9892	CA CHEEK	RADIAL FOREARM FLAP	LATERAL CUTANEOUS NERVE OF FOREARM	SENSORY BUCCAL BRANCH	DIRECT NEURORRHAPHY	GOOD	GOOD	GOOD	75%	EXCELLENT	GOOD	GOOD
15	BAKTHAVATSALAM	65/M	54263	CA TONGUE	RADIAL FOREARM FLAP	MEDIAL CUTANEOUS NERVE OF FOREARM	LINGUAL NERVE	DIRECT NEURORRHAPHY	EXCELLENT	GOOD	GOOD	76%	EXCELLENT	GOOD	EXCELLENT
16	KUMARIAH	50/M	73647	CA CHEEK	RADIAL FOREARM FLAP	LATERAL CUTANEOUS NERVE OF FOREARM	SENSORY BUCCAL BRANCH	DIRECT NEURORRHAPHY	GOOD	GOOD	EXCELLENT	82%	EXCELLENT	GOOD	GOOD
17	POONGAVANAM	54/F	98345	CA ALVEOLUS MANDIBLE	FREE FIBULA	SUPERFICIAL PERONEAL NERVE	GREATER AURICULAR NERVE	DIRECT NEURORRHAPHY	GOOD	GOOD	GOOD	68%	EXCELLENT	GOOD	GOOD
18	GANAPATHY	43/M	87645	CA ALVEOLUS MANDIBLE	FREE FIBULA	SUPERFICIAL PERONEAL NERVE	GREATER AURICULAR NERVE	DIRECT NEURORRHAPHY	GOOD	GOOD	GOOD	69%	EXCELLENT	EXCELLENT	EXCELLENT
19	KANNIAH	58/	53	CA ALVEOLUS MANDIBLE	FREE FIBUL	SUPERFICIAL PERONEAL	GREATER	DIRECT NEURORRHA	EXCELLE	EXCELLE	GOOD	71%	EXCELLE	EXCELLE	EXCELLENT

		M	658		A	NERVE	AURICULAR NERVE	PHY	NT	NT			NT	NT	
20	VALLIAMMAL	58/F	24357	CA ALVEOLUS MANDIBLE	FREE FIBULA	SUPERFICIAL PERONEAL NERVE	SENSORY BUCCAL BRANCH	DIRECT NEURORRHAPHY	EXCELLENT	GOOD	GOOD	70%	EXCELLENT	GOOD	GOOD
21	THANGIAH	49/M	53647	CA ALVEOLUS MANDIBLE	FREE FIBULA	SUPERFICIAL PERONEAL NERVE	SENSORY BUCCAL BRANCH	DIRECT NEURORRHAPHY	GOOD	GOOD	GOOD	65%	EXCELLENT	GOOD	GOOD
22	ELANGOVAN	70/M	24356	CA ALVEOLUS MANDIBLE	FREE FIBULA	SUPERFICIAL PERONEAL NERVE	GREATER AURICULAR NERVE	DIRECT NEURORRHAPHY	GOOD	GOOD	GOOD	72%	EXCELLENT	GOOD	GOOD
3	ISRAEL	59/M	64757	CA ALVEOLUS MANDIBLE	FREE FIBULA	SUPERFICIAL PERONEAL NERVE	SENSORY BUCCAL BRANCH	DIRECT NEURORRHAPHY	GOOD	GOOD	GOOD	72%	EXCELLENT	GOOD	GOOD
24	KANNAN	38/M	74546	POST TRAUMATIC MAXILLARY DEFECT	FREE FIBULA	SUPERFICIAL PERONEAL NERVE	SENSORY BUCCAL BRANCH	DIRECT NEURORRHAPHY	EXCELLENT	GOOD	GOOD	68%	EXCELLENT	EXCELLENT	EXCELLENT
25	GUNASEKARAN	52/M	6475	CA ALVEOLUS MANDIBLE	FREE FIBULA	SUPERFICIAL PERONEAL NERVE	GREATER AURICULAR NERVE	DIRECT NEURORRHAPHY	GOOD	GOOD	GOOD	65%	EXCELLENT	GOOD	GOOD
2	PARA	62	7	CA ALVEOLUS	FREE	SUPERFICIAL	GREATE	DIRECT	GO	GO	GOO	70%	EXC	GO	EXCELL

6	MASIVAN	/M	5857	MANDIBLE	FIBULA	PERONEAL NERVE	R AURICULAR NERVE	NEURORRHAPHY	OD	OD	D		ELLENT	OD	ENT
27	KATHIR VEL	68/M	53647	CA ALVEOLUS MANDIBLE	FREE FIBULA	SUPERFICIAL PERONEAL NERVE	GREATER AURICULAR NERVE	DIRECT NEURORRHAPHY	GOOD	GOOD	GOOD	66%	EXCELLENT	GOOD	GOOD
28	SUNDERASAN	63/M	84957	CA ALVEOLUS MANDIBLE	FREE FIBULA	SUPERFICIAL PERONEAL NERVE	SENSORY BUCCAL BRANCH	DIRECT NEURORRHAPHY	GOOD	GOOD	GOOD	57%	EXCELLENT	GOOD	GOOD
29	MARTIN	49/M	6578	POST TRAUMATIC OSTEOMYELITIS MAXILLA	FREE FIBULA	SUPERFICIAL PERONEAL NERVE	SENSORY BUCCAL BRANCH	DIRECT NEURORRHAPHY	EXCELLENT	GOOD	GOOD	77%	EXCELLENT	EXCELLENT	EXCELLENT
30	KASI	52/M	3657	CA ALVEOLUS MANDIBLE	FREE FIBULA	SUPERFICIAL PERONEAL NERVE	SENSORY BUCCAL BRANCH	DIRECT NEURORRHAPHY	GOOD	GOOD	GOOD	70%	EXCELLENT	GOOD	GOOD
31	KUBERAN	48/M	73849	CA ALVEOLUS MANDIBLE	FREE FIBULA	SUPERFICIAL PERONEAL NERVE	GREATER AURICULAR NERVE	DIRECT NEURORRHAPHY	GOOD	GOOD	GOOD	76%	EXCELLENT	GOOD	EXCELLENT
32	KUPPUSAMY	49/M	3647	CA ALVEOLUS MANDIBLE	FREE FIBULA	SUPERFICIAL PERONEAL NERVE	GREATER AURICULAR NERVE	DIRECT NEURORRHAPHY	GOOD	GOOD	GOOD	68%	EXCELLENT	GOOD	GOOD

33	NARAYANAMOORTHY	39/M	75867	CA ALVEOLUS MANDIBLE	FREE FIBULA	SUPERFICIAL PERONEAL NERVE	SENSORY BUCCAL BRANCH	DIRECT NEURORRHAPHY	GOOD	EXCELLENT	EXCELLENT	78%	EXCELLENT	EXCELLENT	EXCELLENT
34	KUMARAN	62/M	93775	CA ALVEOLUS MANDIBLE	FREE FIBULA	SUPERFICIAL PERONEAL NERVE	SENSORY BUCCAL BRANCH	DIRECT NEURORRHAPHY	GOOD	GOOD	GOOD	69%	EXCELLENT	GOOD	GOOD
35	ANBU	22/M	74868	POST TRAUMATIC OSTEOMYELITIS MANDIBLE	FREE FIBULA	SUPERFICIAL PERONEAL NERVE	GREATER AURICULAR NERVE	DIRECT NEURORRHAPHY	GOOD	EXCELLENT	GOOD	70%	EXCELLENT	EXCELLENT	EXCELLENT
36	PANDIAN	61/M	85960	CA ALVEOLUS MANDIBLE	FREE FIBULA	SUPERFICIAL PERONEAL NERVE	SENSORY BUCCAL BRANCH	DOUBLE ANASTOMOSIS WITH NERVE GRAFT	SATISFACTORY	SATISFACTORY	UNSATISFACTORY	40%	SATISFACTORY	SATISFACTORY	SATISFACTORY
37	MURUGAN	56/M	9378	CA ALVEOLUS MANDIBLE	FREE FIBULA	SUPERFICIAL PERONEAL NERVE	GREATER AURICULAR NERVE	DIRECT NEURORRHAPHY	GOOD	GOOD	GOOD	69%	EXCELLENT	GOOD	EXCELLENT
38	NANDHAN	55/M	85870	CA ALVEOLUS MANDIBLE	FREE FIBULA	SUPERFICIAL PERONEAL NERVE	GREATER AURICULAR NERVE	DIRECT NEURORRHAPHY	GOOD	GOOD	GOOD	65%	EXCELLENT	GOOD	GOOD
39	MUNIAPPAN	60/M	7586	CA ALVEOLUS MANDIBLE	FREE FIBULA	SUPERFICIAL PERONEAL NERVE	GREATER AURICULAR	DIRECT NEURORRHAPHY	GOOD	GOOD	GOOD	70%	EXCELLENT	GOOD	GOOD

			8				NERVE								
40	GOPALAKRISHNAN	49/M	35465	CA MAXILLA	FREE FIBULA	SUPERFICIAL PERONEAL NERVE	GREATER AURICULAR NERVE	DIRECT NEURORRHAPHY	GOOD	GOOD	GOOD	71%	EXCELLENT	GOOD	EXCELLENT
41	KATHAPPAN	62/M	5868	CA ALVEOLUS MANDIBLE	FREE FIBULA	SUPERFICIAL PERONEAL NERVE	GREATER AURICULAR NERVE	DIRECT NEURORRHAPHY	GOOD	GOOD	GOOD	69%	EXCELLENT	GOOD	GOOD
42	RAVICHANDRAN	52/M	85969	CA ALVEOLUS MANDIBLE	FREE FIBULA	SUPERFICIAL PERONEAL NERVE	GREATER AURICULAR NERVE	DIRECT NEURORRHAPHY	GOOD	GOOD	GOOD	67%	EXCELLENT	GOOD	GOOD

PROFORMA

Name: plastic surgery unit

Age:

Sex:

IP No:

Date of admission

Date of surgery:

Presenting complaints:

Treatment history:

Past and personal history:

Family history:

General examination:

Built: Nutritional status:

Cardiovascular system:

Respiratory system:

Abdominal examination:

Local examination:

Regional lymph nodes:

Diagnosis:

Treatment plan:

Investigations:

Procedure:

Donor nerve

Recipient nerve:

Follow up:

Outcome of function:

Speech

Swallowing

mastication

Proprioception:Two point discrimination

Sensation: pain and temperature

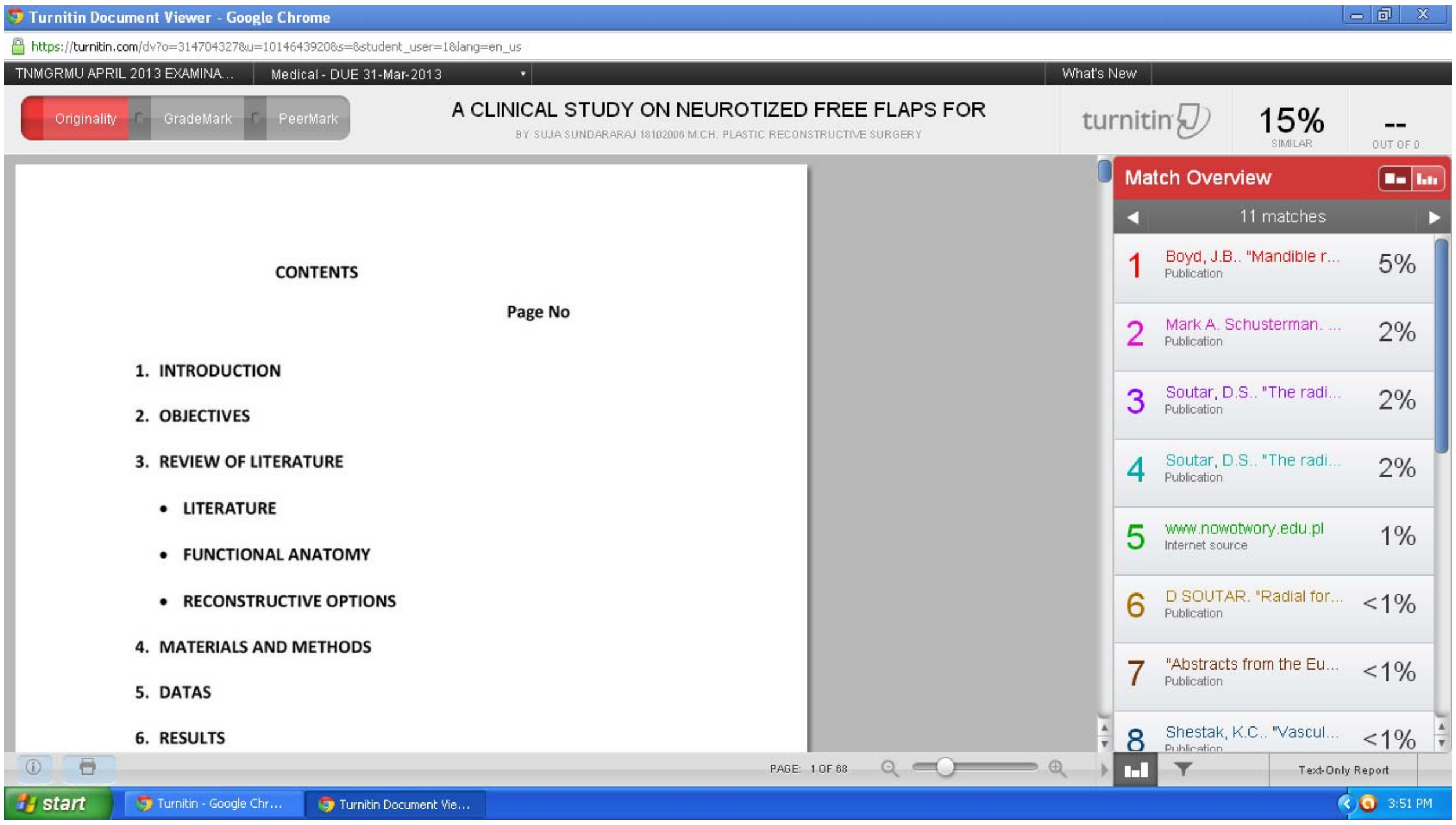
Turnitin Document Viewer - Google Chrome
https://turnitin.com/dv?o=314704327&u=1014643920&s=&student_user=1&lang=en_us
TNMGRMU APRIL 2013 EXAMINA...
Medical - DUE 31-Mar-2013
What's New
Originality
GradeMark
PeerMark
A CLINICAL STUDY ON NEUROTIZED FREE FLAPS FOR
BY SUJA SUNDARARAJ 18102006 M.CH. PLASTIC RECONSTRUCTIVE SURGERY
turnitin
15%
SIMILAR
--
OUT OF 0
CONTENTS
Page No
1. INTRODUCTION
2. OBJECTIVES
3. REVIEW OF LITERATURE
• LITERATURE
• FUNCTIONAL ANATOMY
• RECONSTRUCTIVE OPTIONS
4. MATERIALS AND METHODS
5. DATAS
6. RESULTS
Match Overview
11 matches
1 Boyd, J.B.. "Mandible r... Publication 5%
2 Mark A. Schusterman. ... Publication 2%
3 Soutar, D.S.. "The radi... Publication 2%
4 Soutar, D.S.. "The radi... Publication 2%
5 www.nowotwory.edu.pl Internet source 1%
6 D SOUTAR. "Radial for... Publication <1%
7 "Abstracts from the Eu... Publication <1%
8 Shestak, K.C.. "Vascul... <1%
PAGE: 1 OF 68
Text-Only Report
start
Turnitin - Google Chr...
Turnitin Document Vie...
3:51 PM